
Atlas de Micologia Médica

Lâminas

Jeferson Carvalhaes de
Oliveira

MICOLOGIA MÉDICA

Atlas

Bem-vindo

Reunimos neste Atlas imagens importantes relacionadas à “Micologia Médica”, apresentando o estudo dos fungos e micoses através do diagnóstico micológico.

Trata-se de um material educativo que visa facilitar o aprendizado dos interessados em micologia. Através de uma sequência de imagens, com um enunciado simples e de importância para o diagnóstico final, o aluno tenta responder ao que se pede e no final confere as suas respostas com o gabarito. Este Atlas mostra de forma atual: os fungos e as micoses e, conseqüentemente, o diagnóstico.

Todas as informações foram especialmente ilustradas e poderão ser impressas para que o usuário tenha uma ideia mais clara da micromorfologia dos fungos e possa aprender com maior facilidade. Este material faz parte de nosso compromisso com você, em oferecer o que existe de mais atual para auxiliá-lo no seu trabalho.

Mãos à obra!

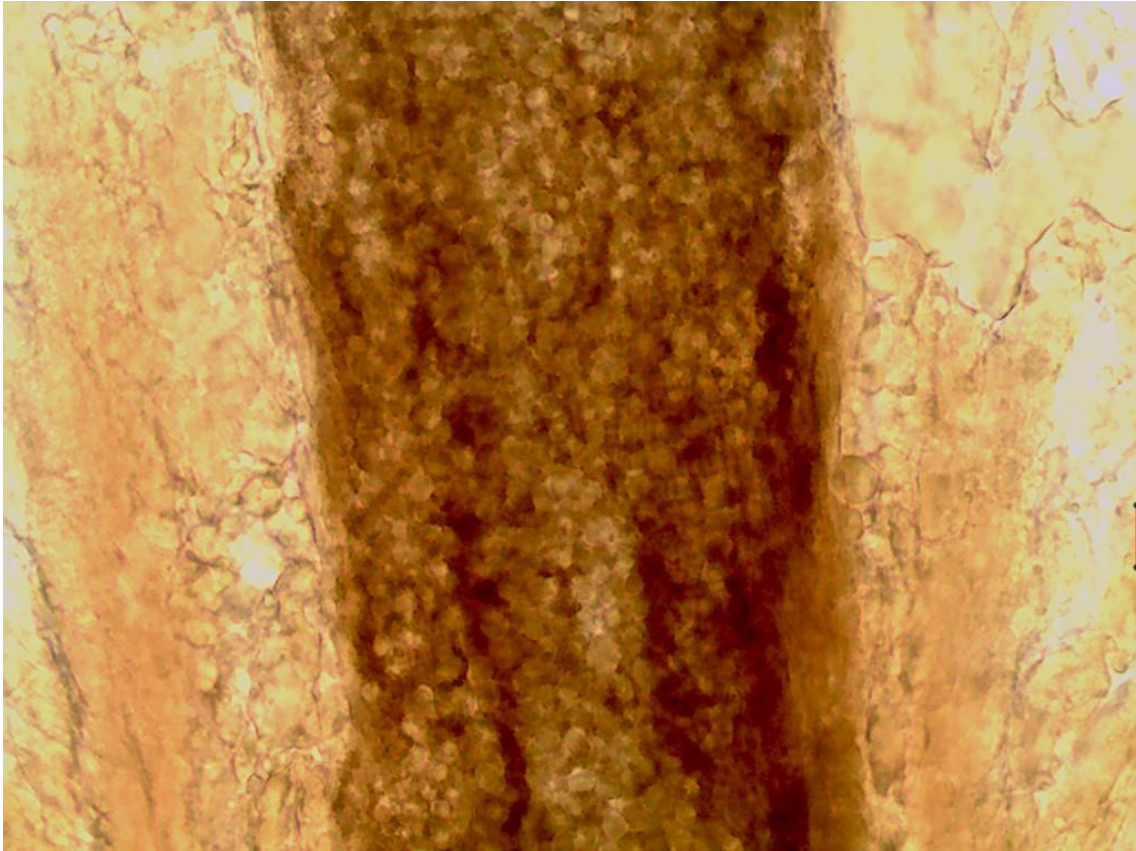
Para executar o exercício, utilize uma folha em branco e seguindo a numeração coloque a descrição e o diagnóstico em relação a cada **lâmina**. Confira no final a sua resposta com o gabarito.

Aviso Importante

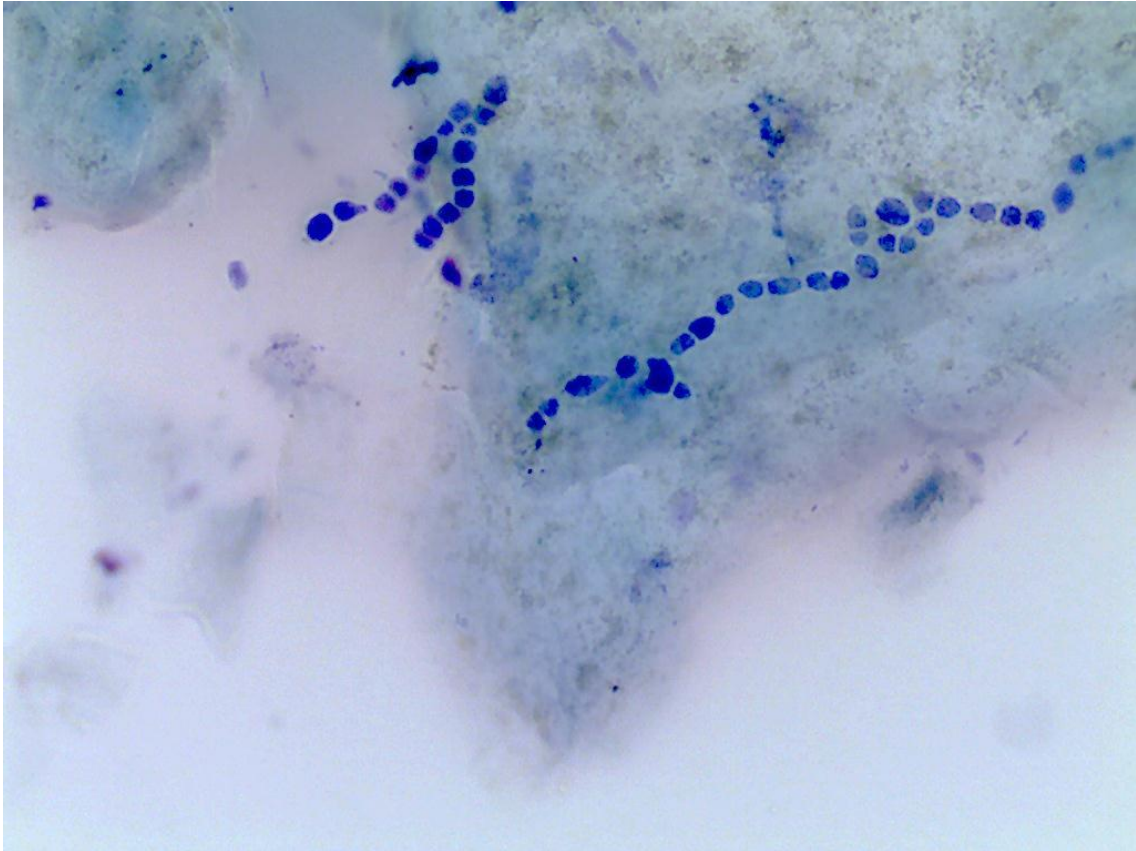
Toda a documentação técnica deste Atlas é obra, protegida pelas leis de Direitos Autorais _ Ministério da Cultura / Fundação BIBLIOTECA NACIONAL. Nenhuma parte desta publicação pode ser copiada sem o consentimento expresso, por escrito, autor.

Em relação a cada lâmina descreva as suas características (nome das estruturas) e dê o diagnóstico.

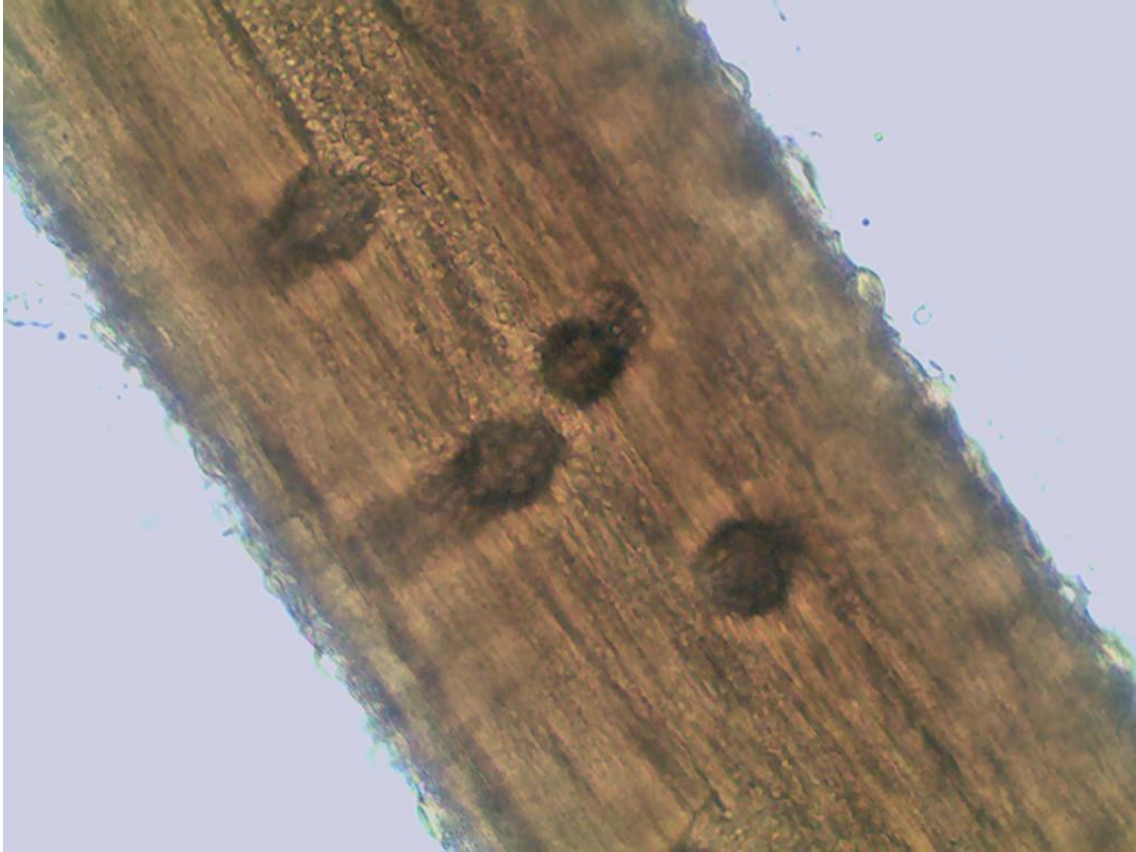Lâmina 1: Exame direto, 400x.




Lâmina 2: Exame direto corado pelo Giemsa, 400x.



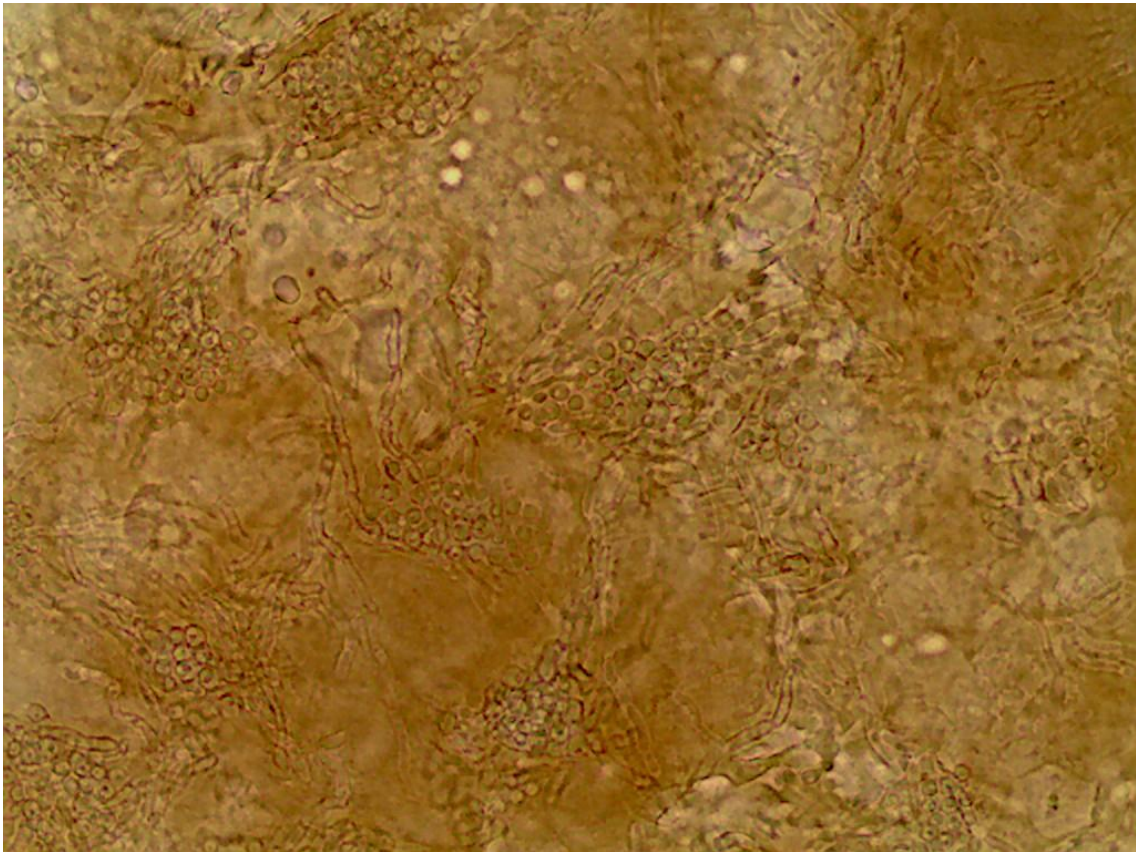
Lâmina 3: Teste de perfuração serve para que finalidade?



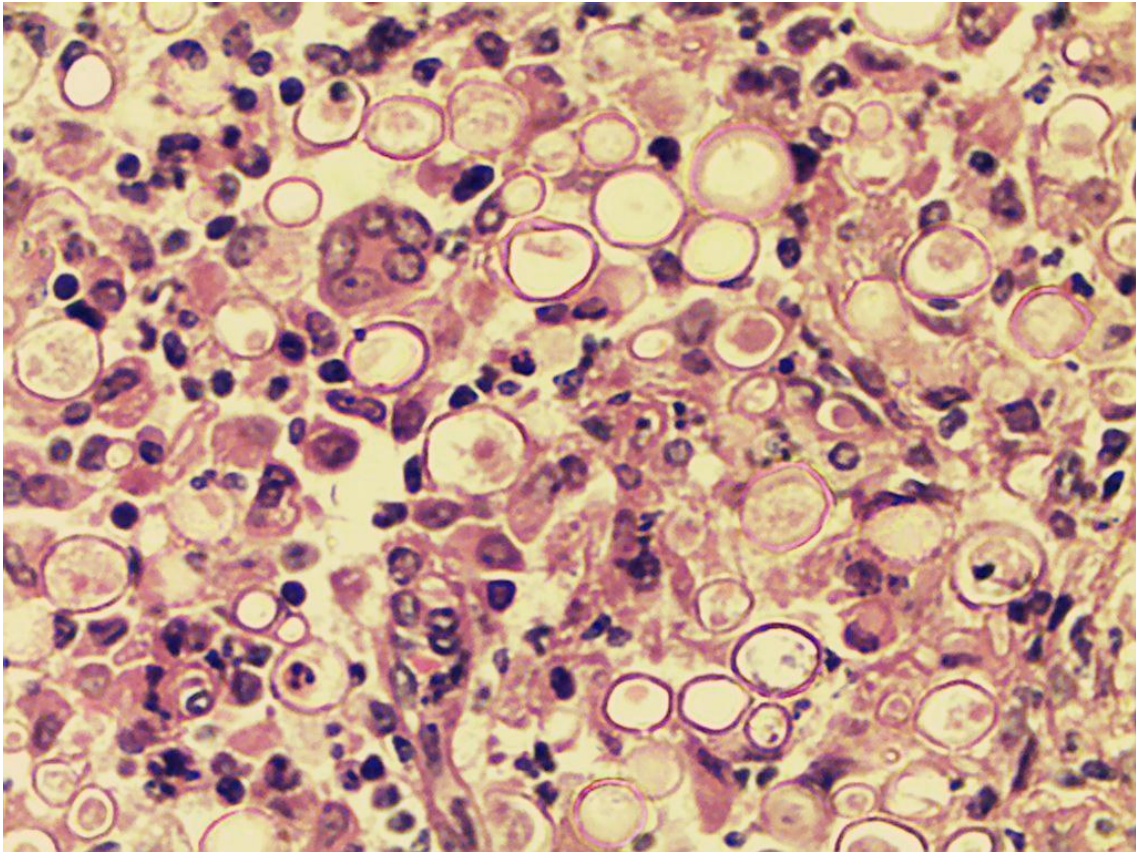
Lâmina 4: Exame direto de cabelo, criança de 9 anos, 400x:



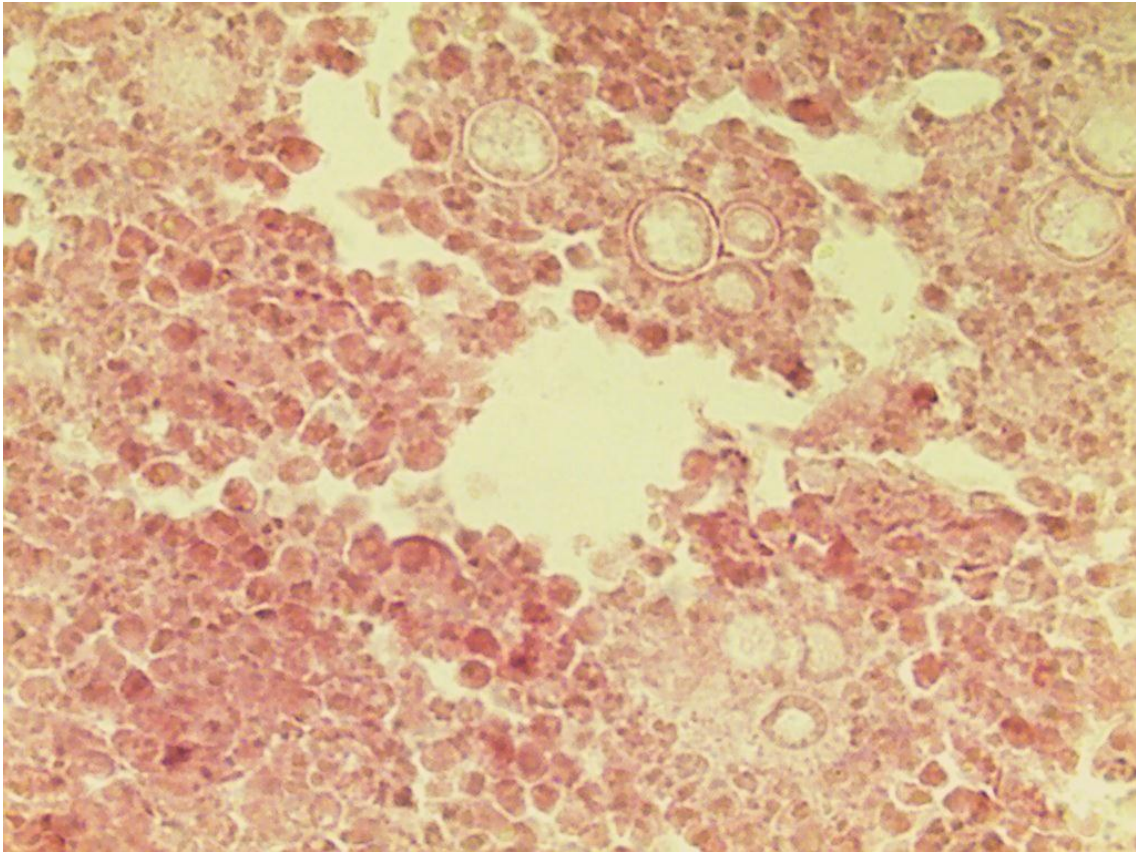
Lâmina 5: Exame direto 400x.



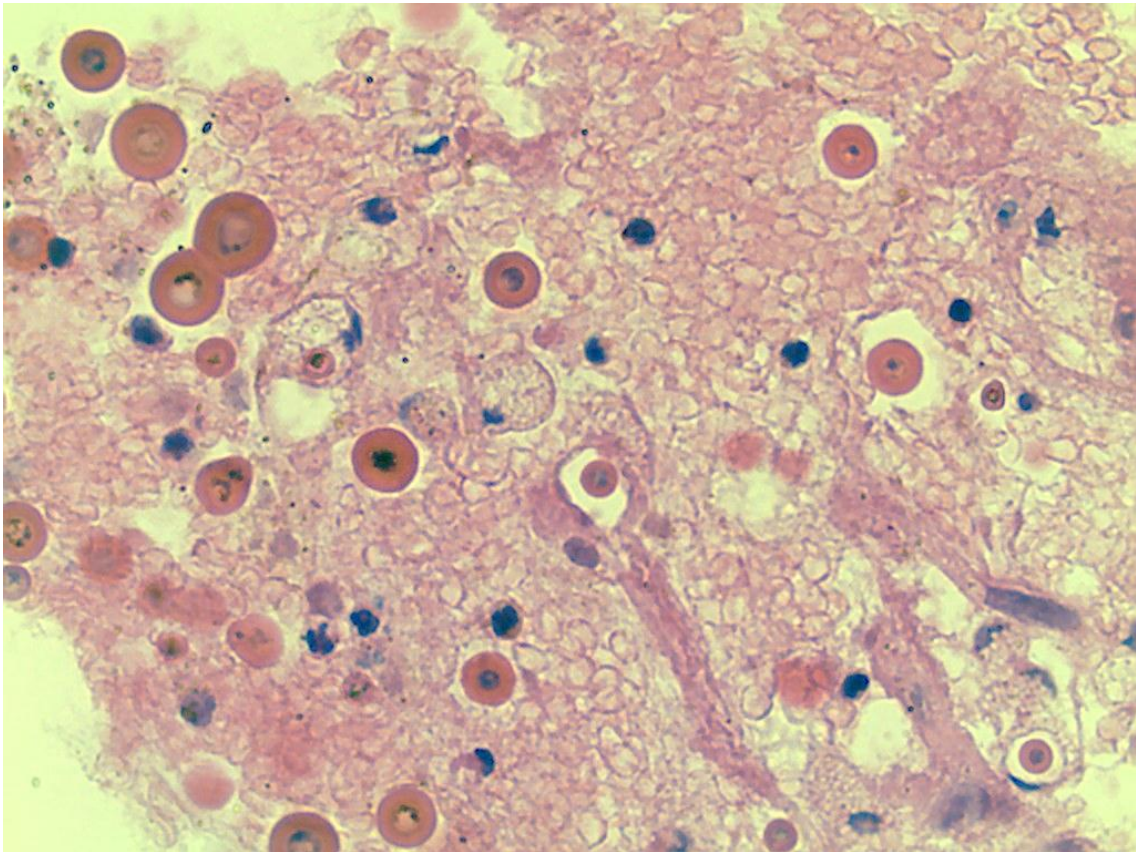
Lâmina 6: Exame histopatológico corado pelo HE, 400x.



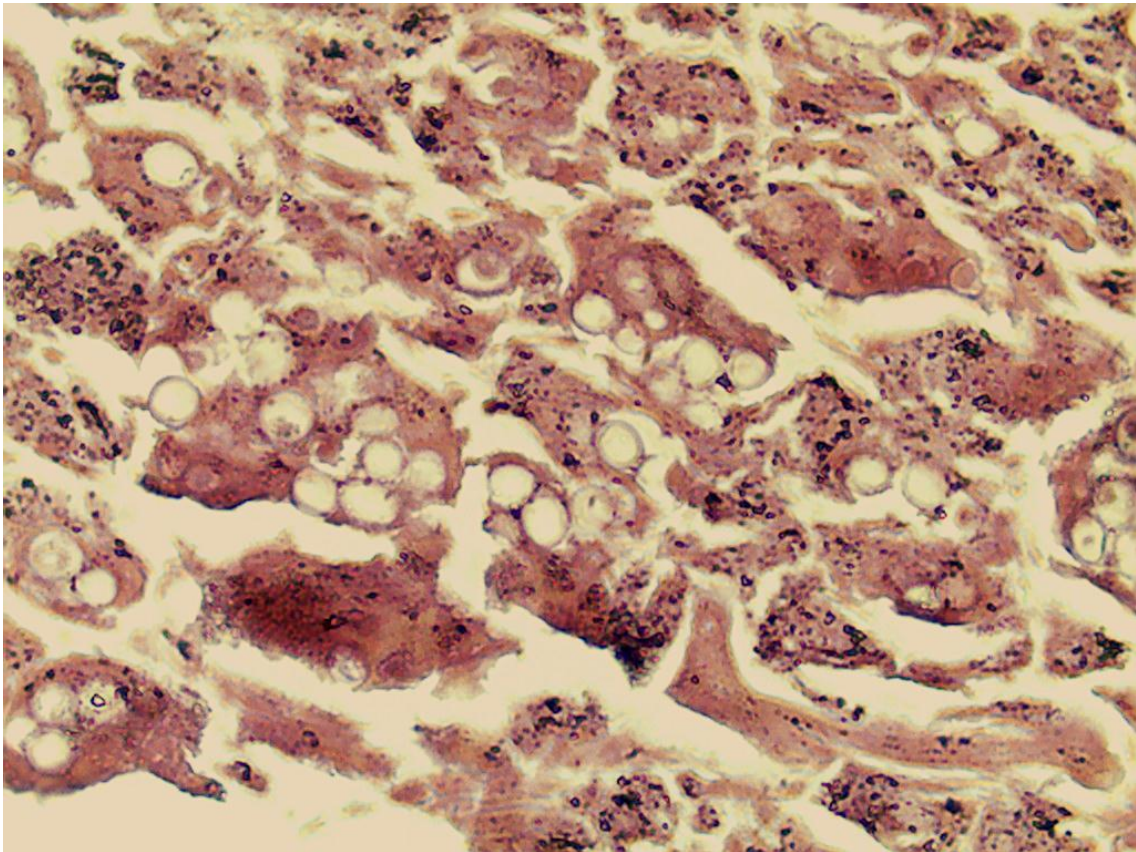
Lâmina 7: Exame histopatológico corado pelo HE, 400x



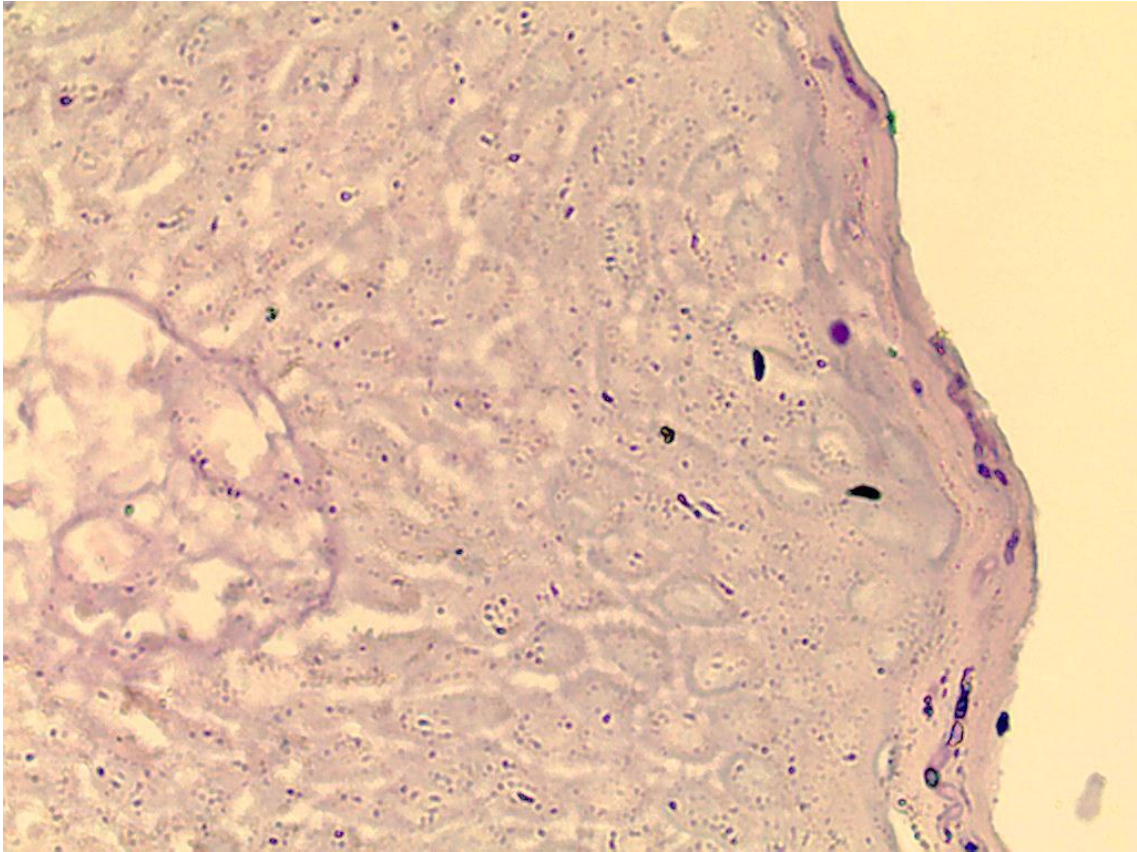
Lâmina 8: Exame histopatológico corado pelo PAS, 400x



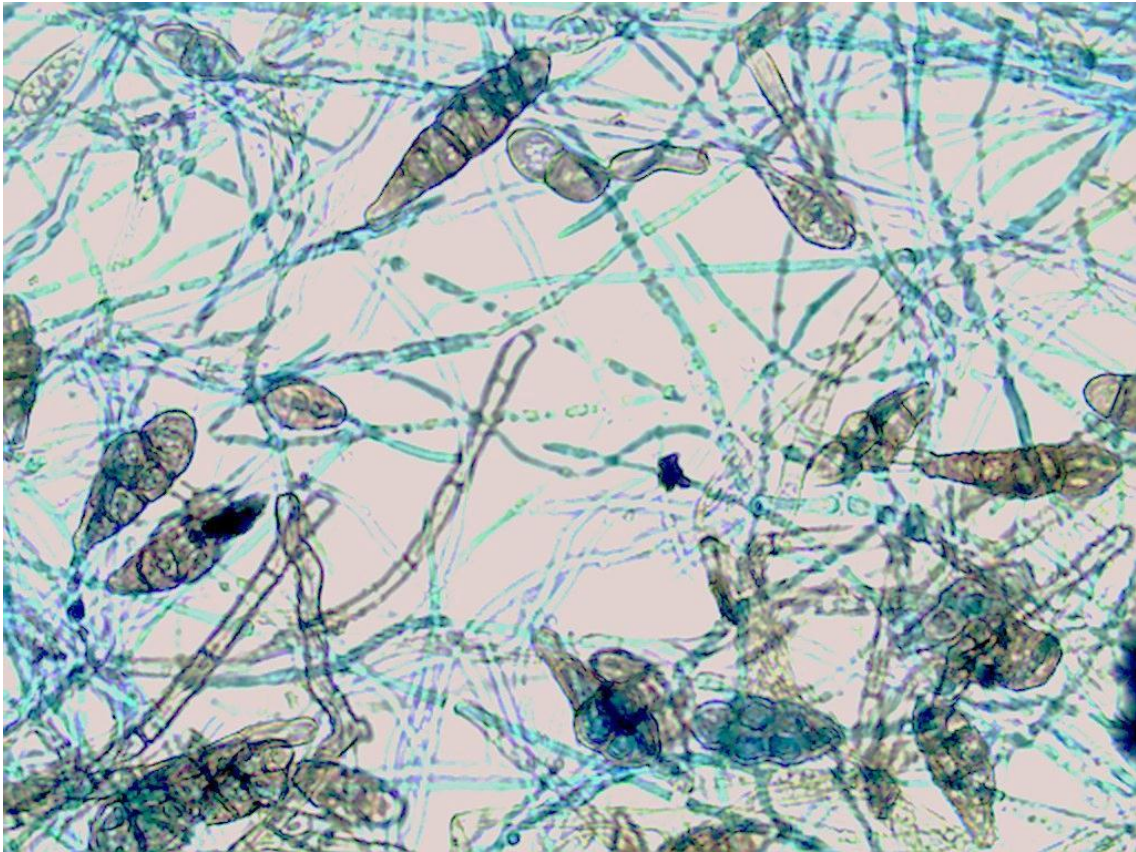
Lâmina 9: Exame histopatológico corado pelo HE, 400x



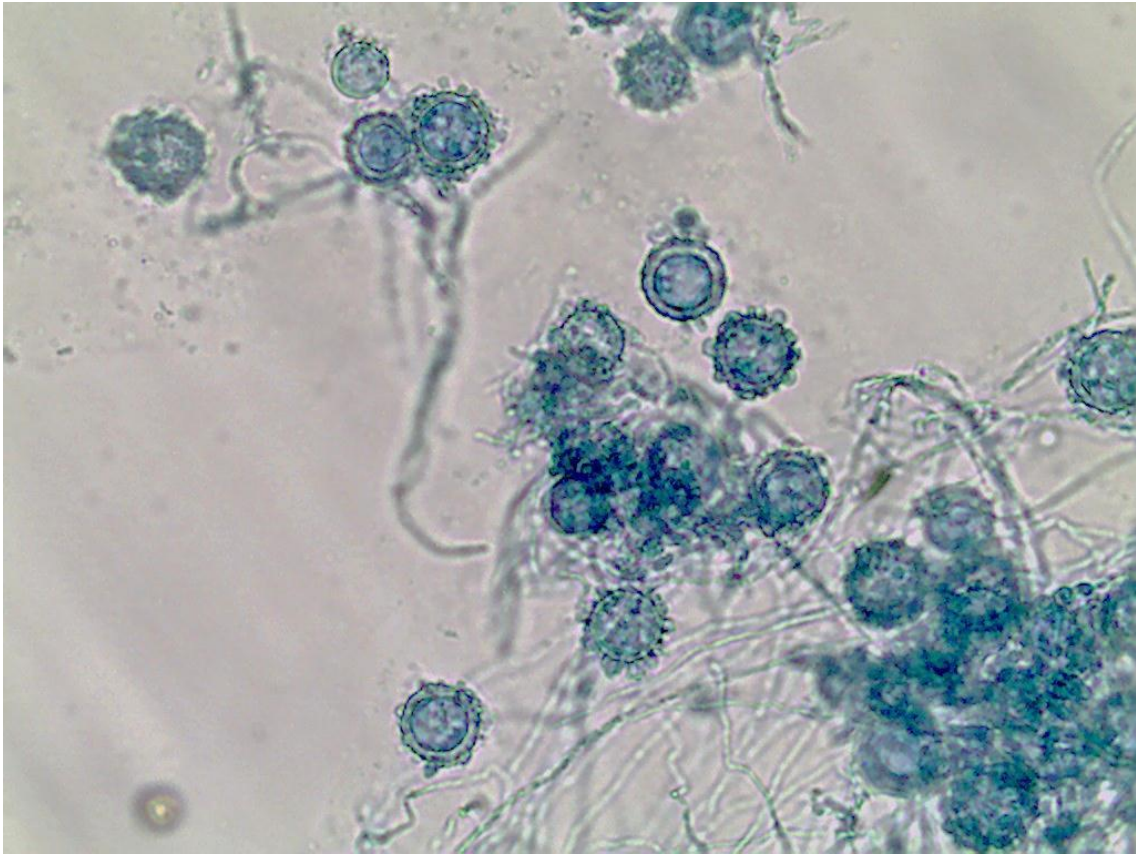
Lâmina 10: Exame histopatológico corado pelo PAS, 400x



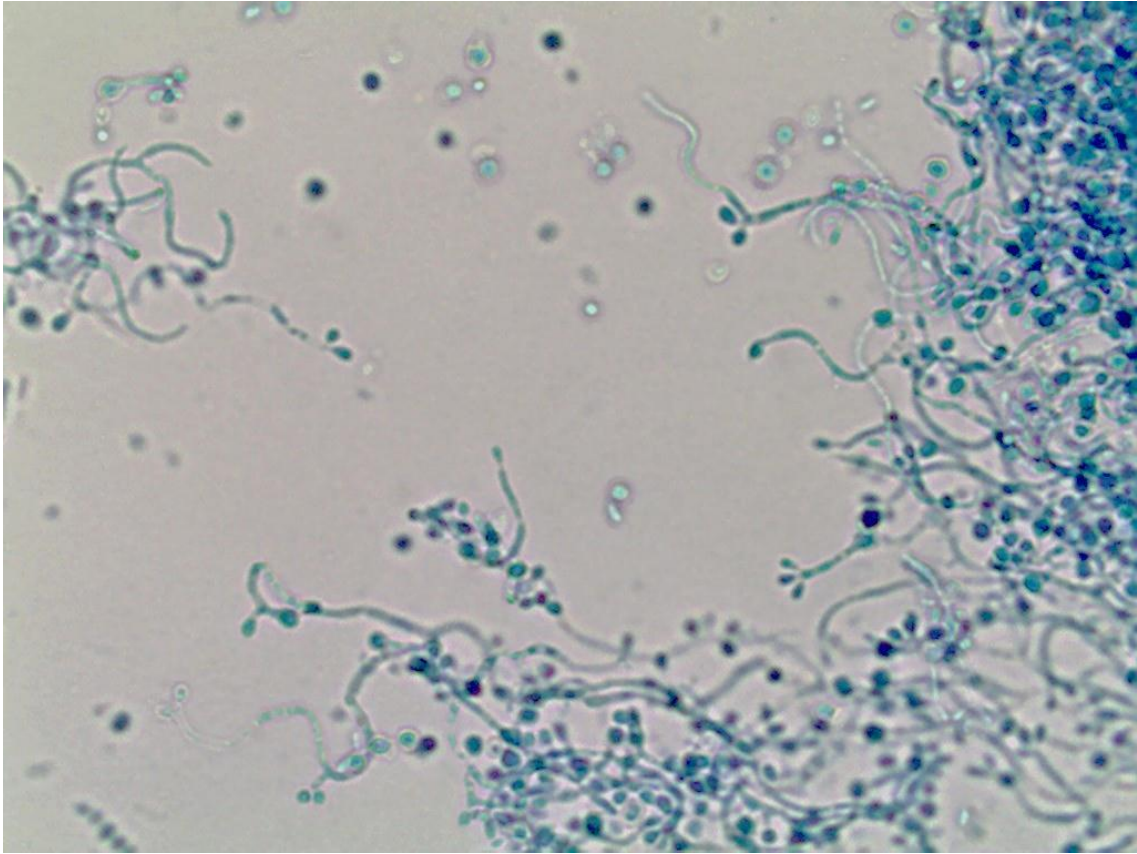
Lâmina 11: Micromorfologia de colônia de fungo demácio, 400x.



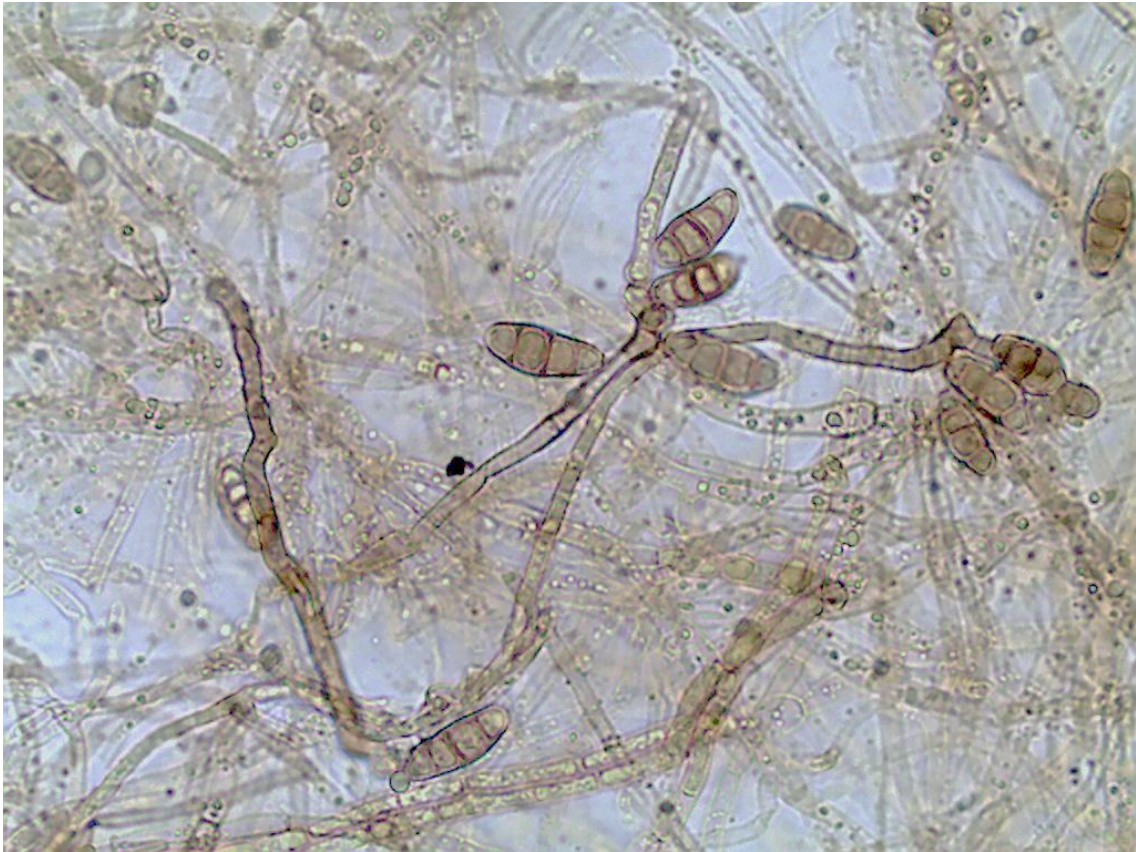
Lâmina 12: Micromorfologia de colônia de fungo, 400x.



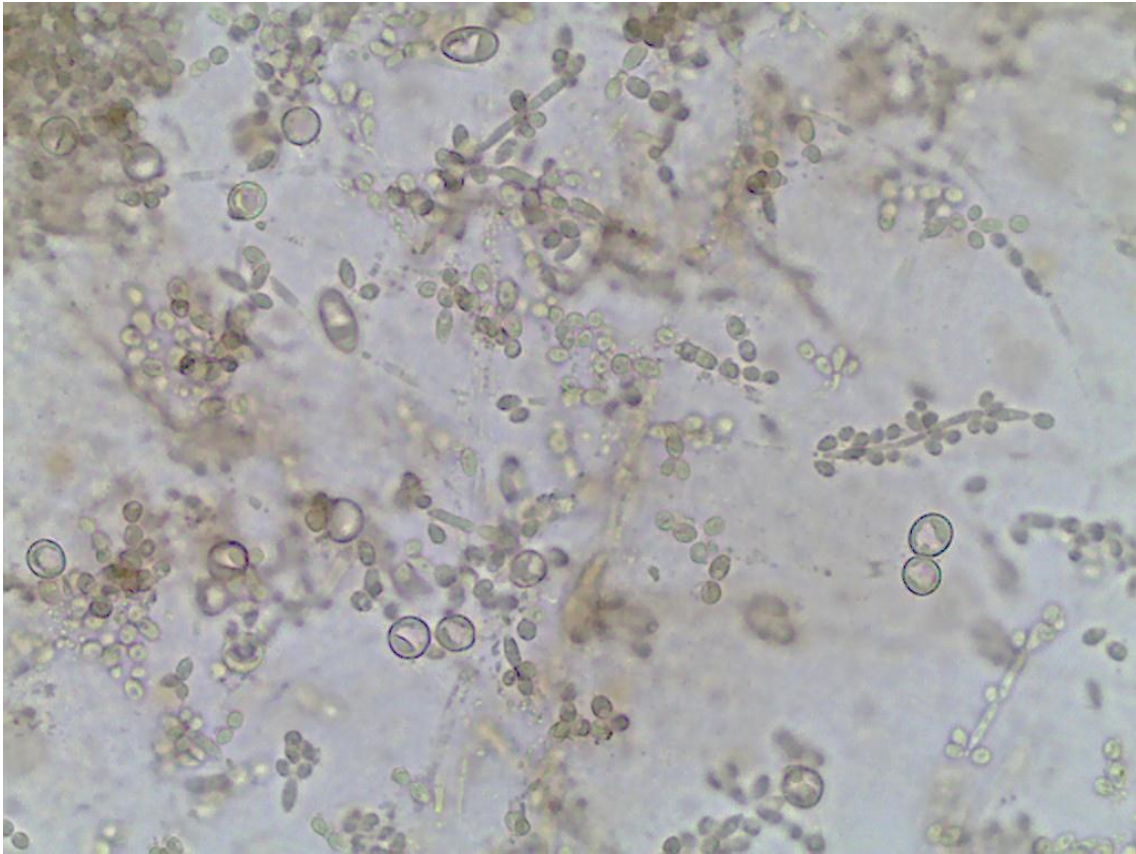
Lâmina 13: Micromorfologia de colônia de fungo, 400x.



Lâmina 14: Micromorfologia de colônia de fungo demácio, 400x.

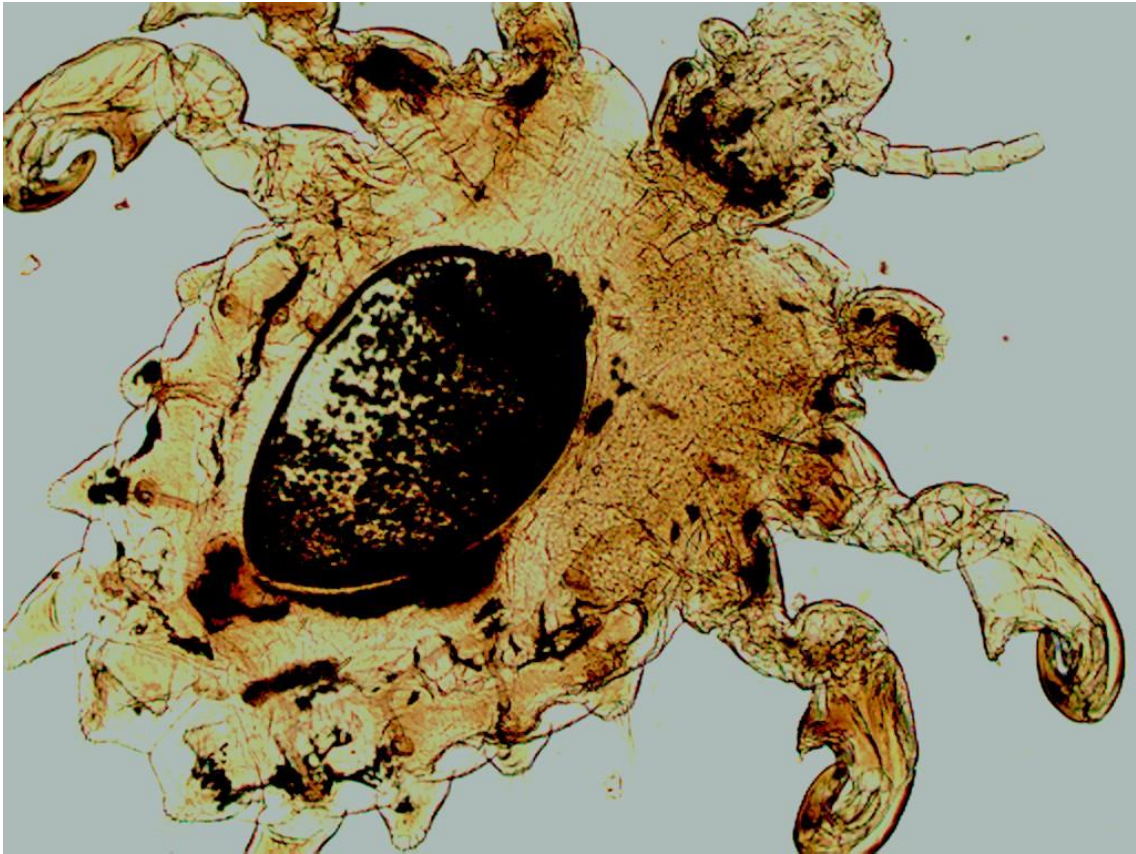


Lâmina 15: Micromorfologia de colônia de fungo, 400x.

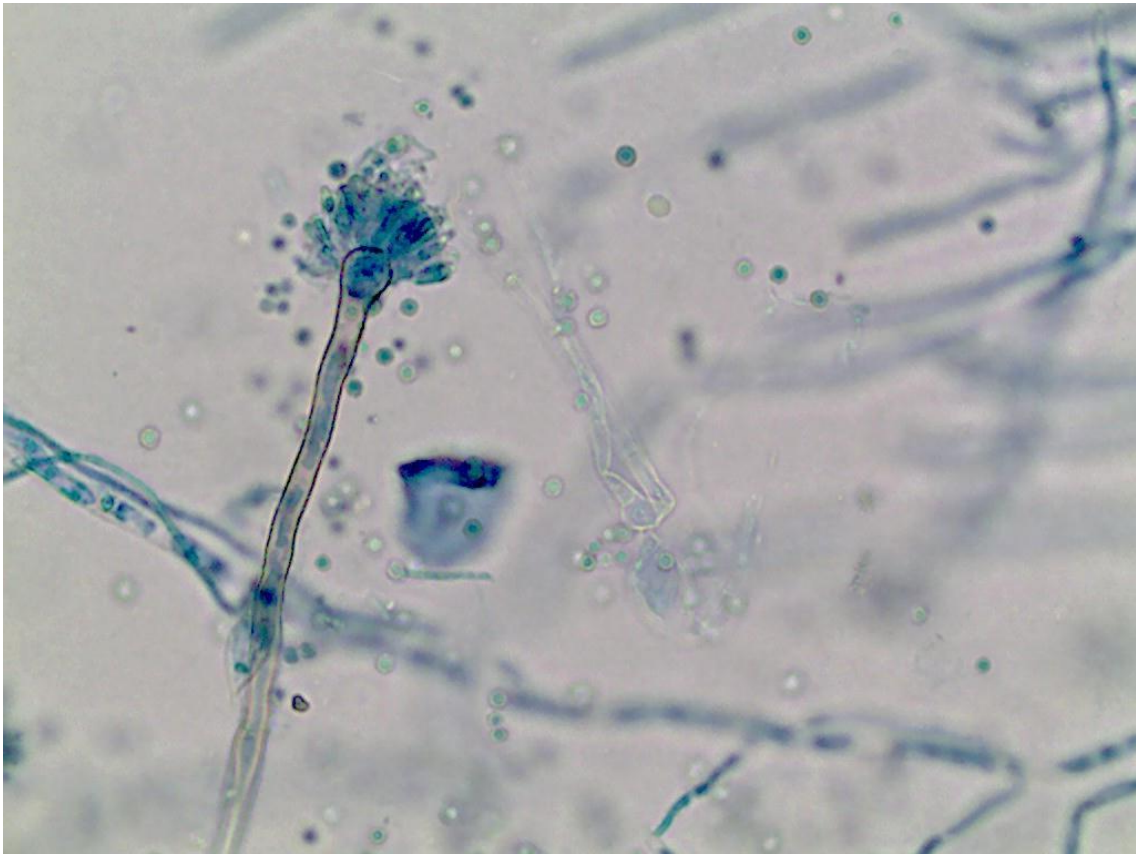


Lâmina 16: Qual o diagnóstico deste raspado cutâneo de região inguinal?

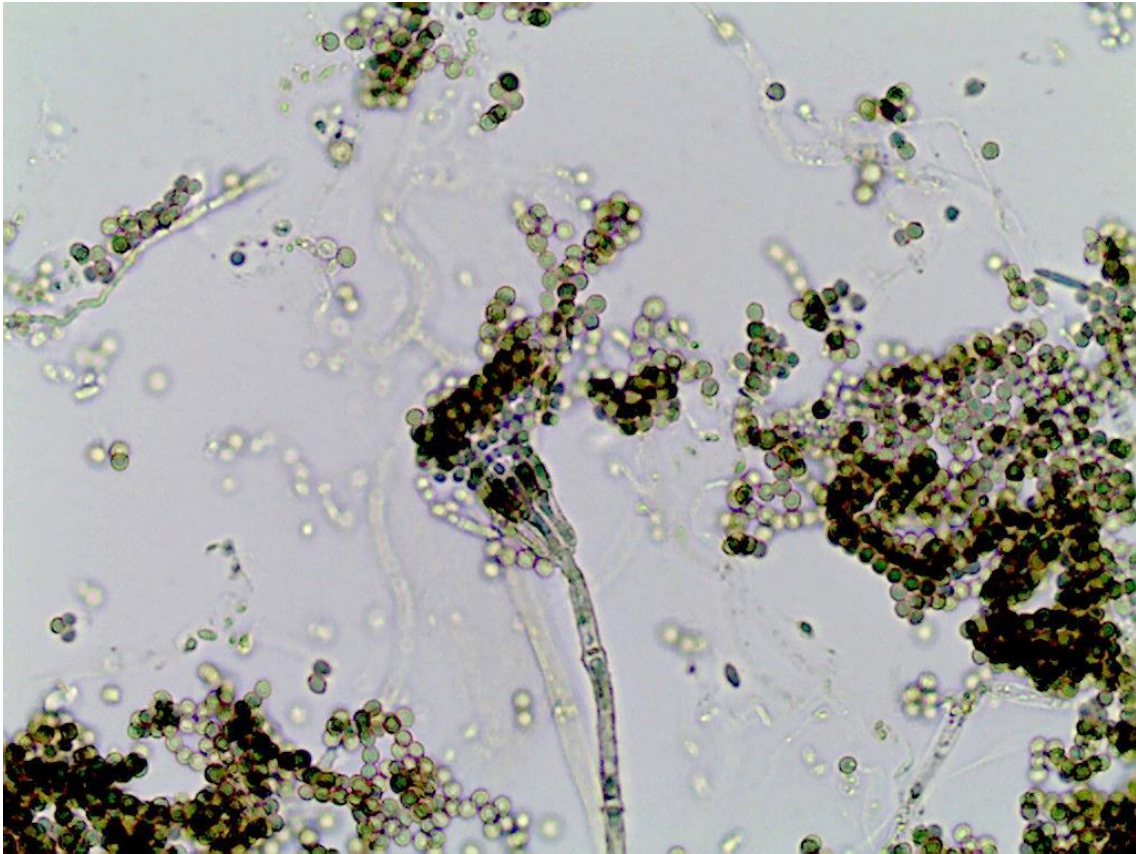
17



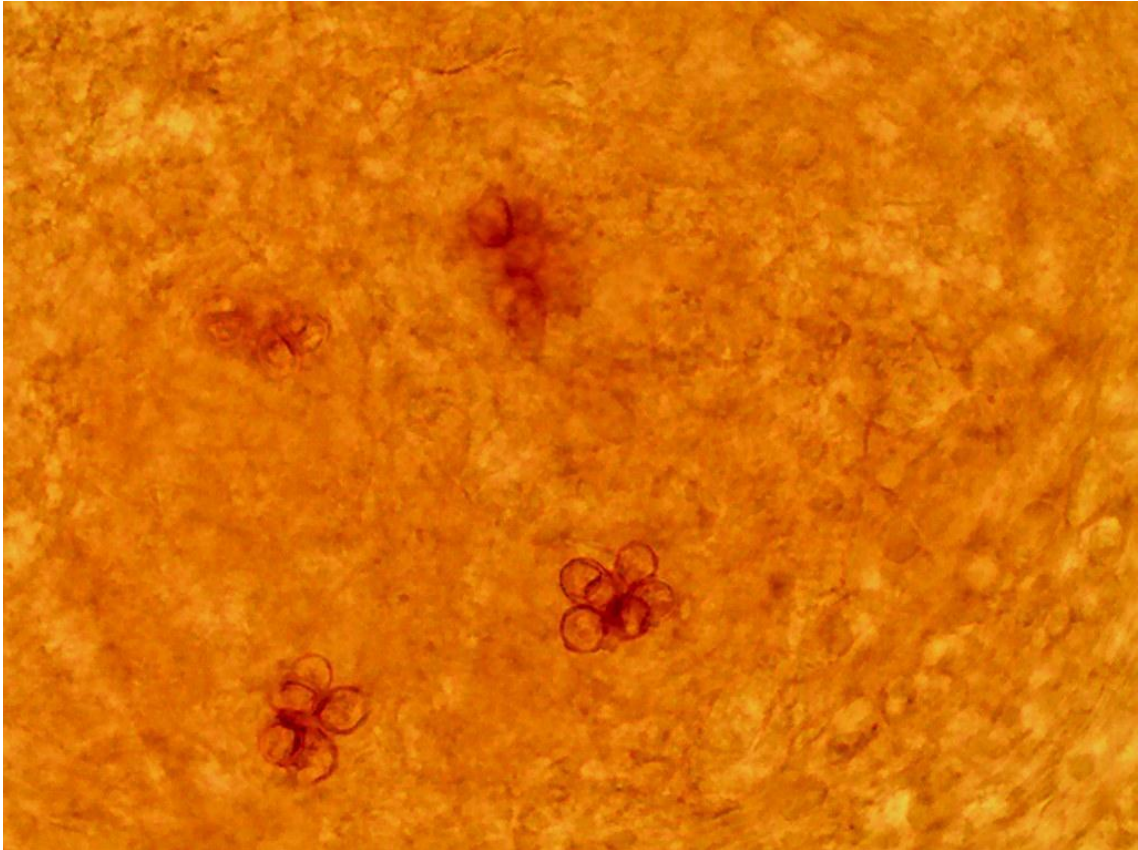
Lâmina 17: Micromorfologia de colônia de fungo, 400x.



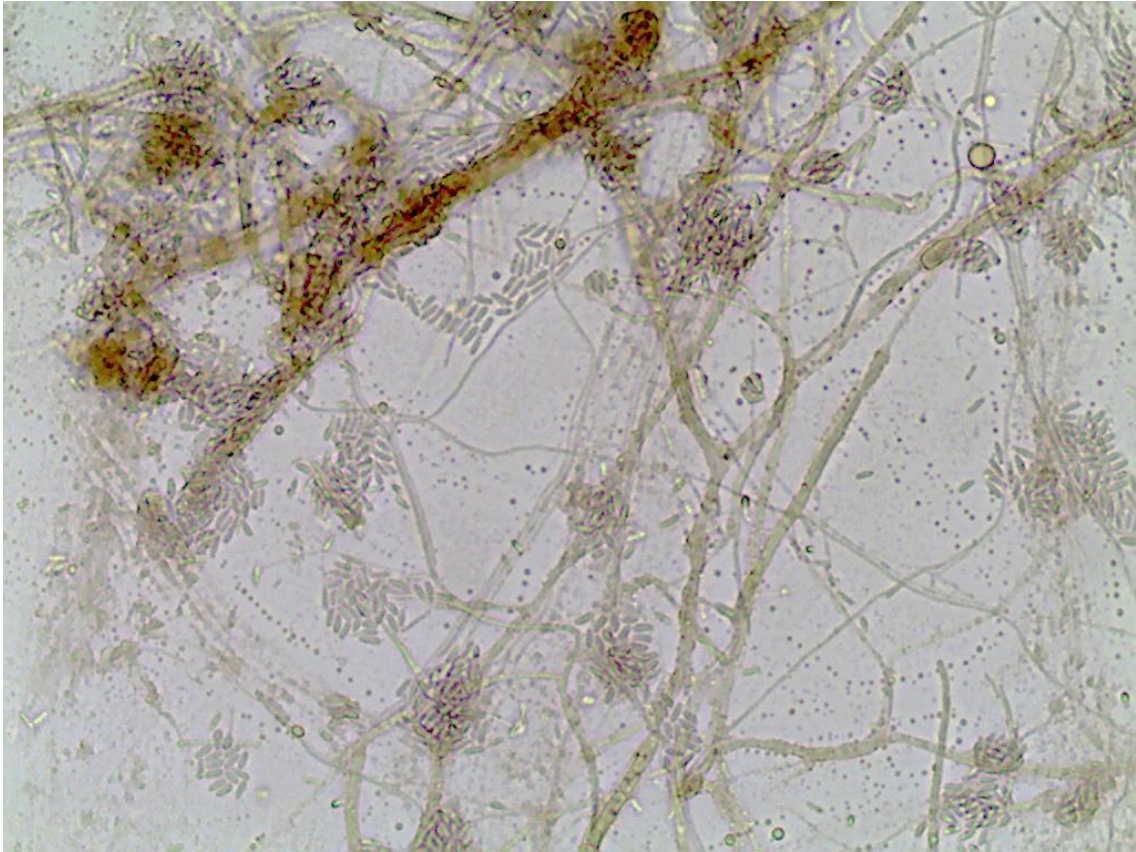
Lâmina 18: Micromorfologia de colônia de fungo, 400x.



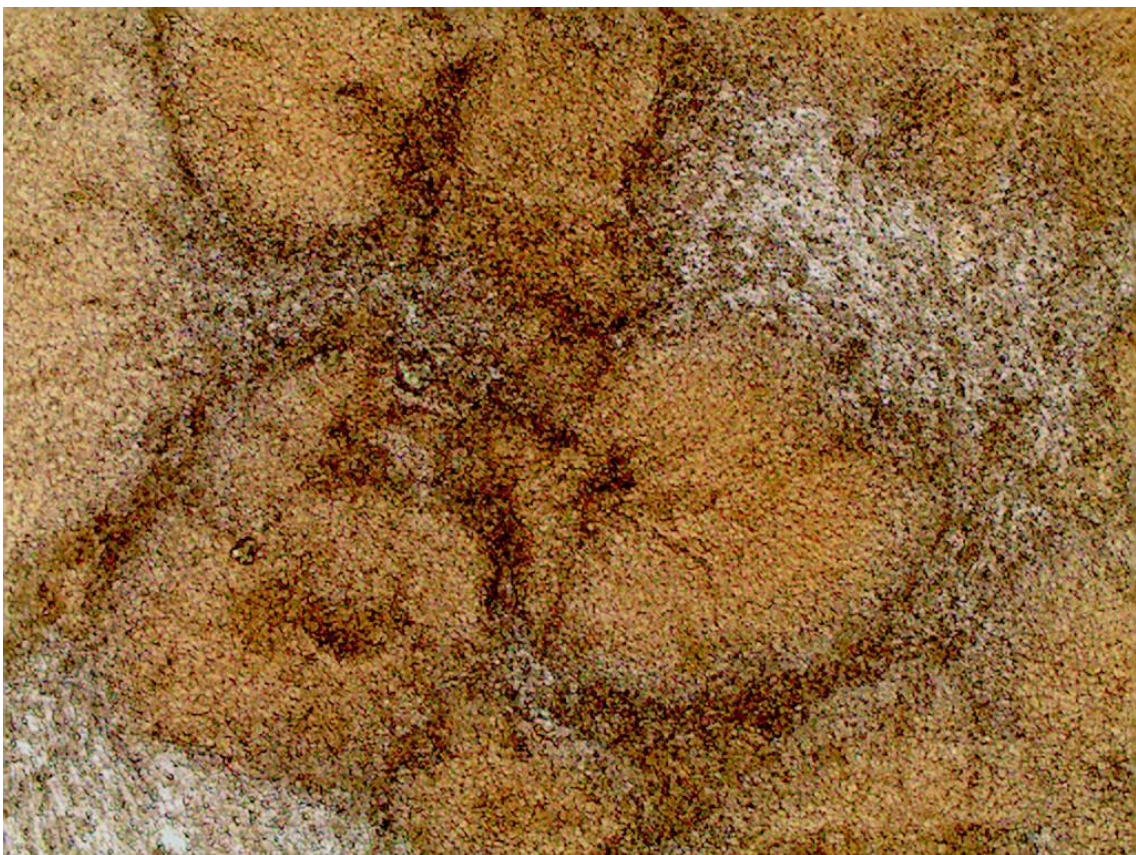
Lâmina 19: Exame direto de biópsia nódulo verrucóide, 400x.



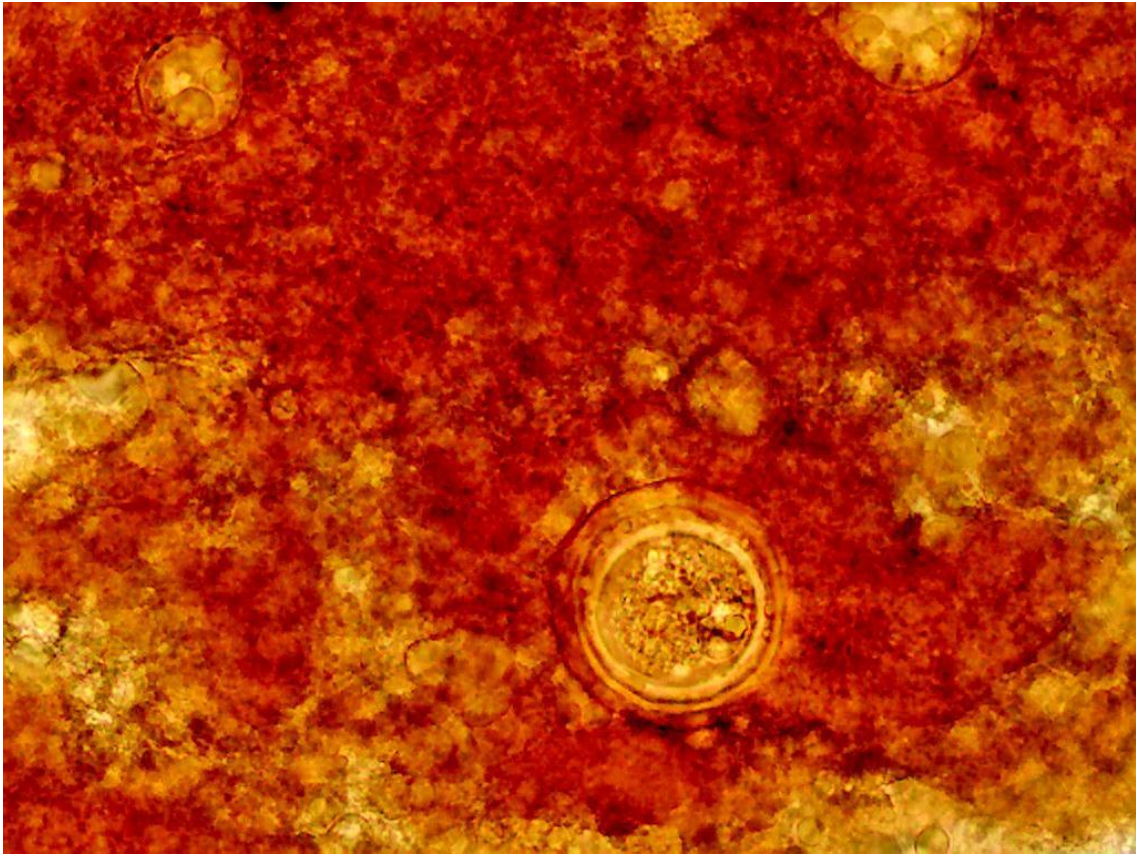
Lâmina 20: Micromorfologia de colônia de fungo, 400x



Lâmina 21: Exame direto de biópsia lesão tumoral na perna, 100x e 400x.

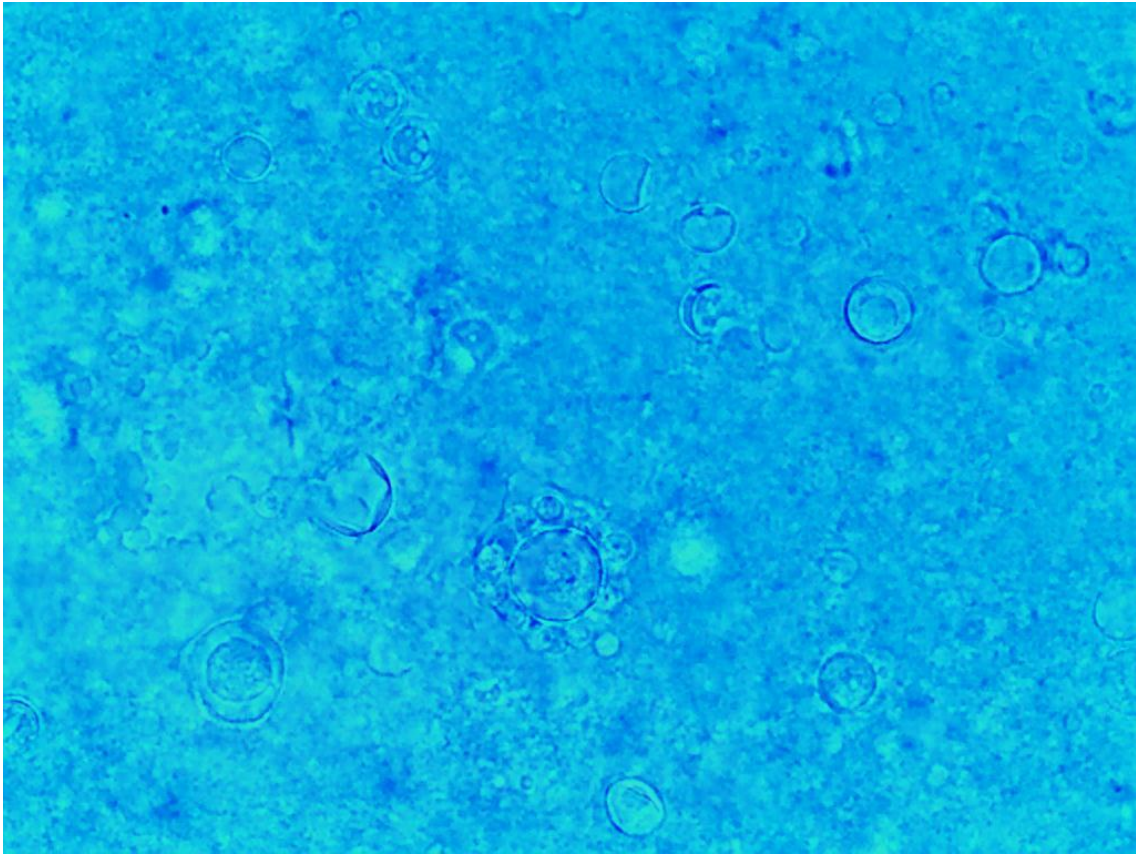


Lâmina 22: Exame direto de biópsia de lesão cutânea, 400x.

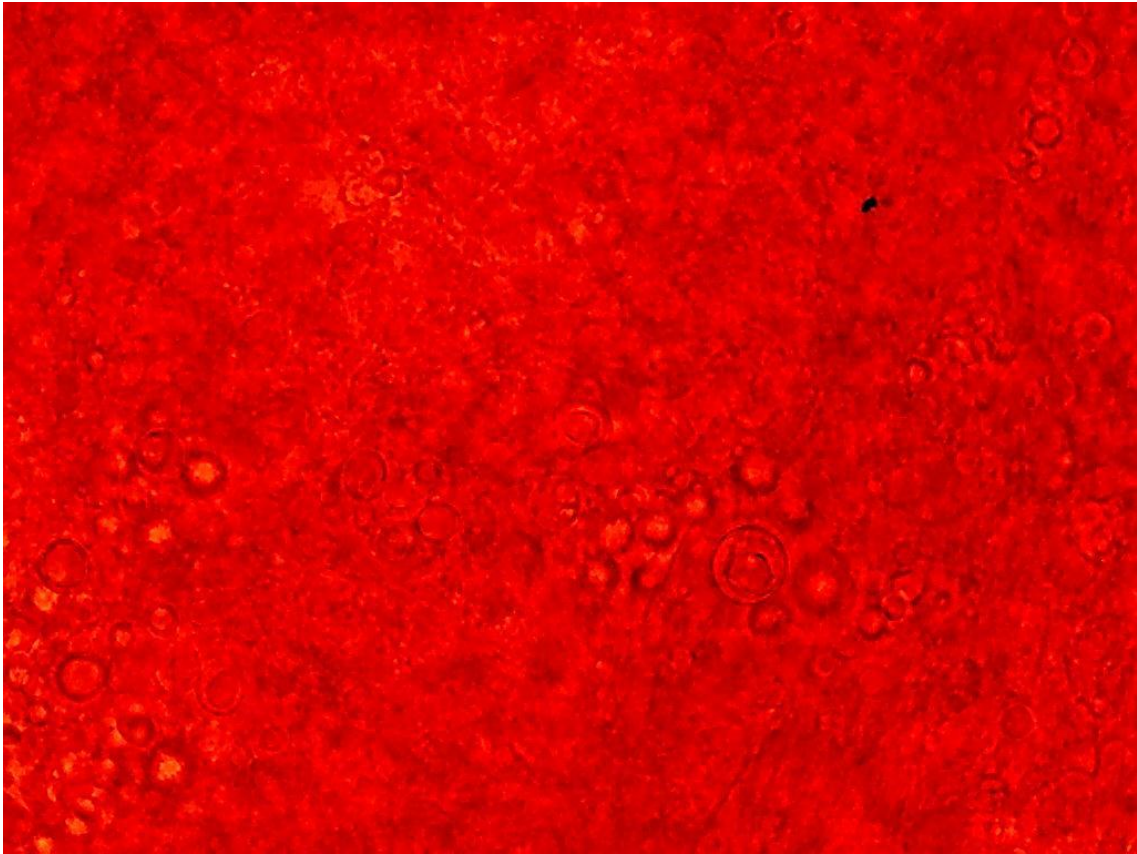


Lâmina 23: Exame direto de secreção de nódulo linfático pescoço, com azul algodão 400x.

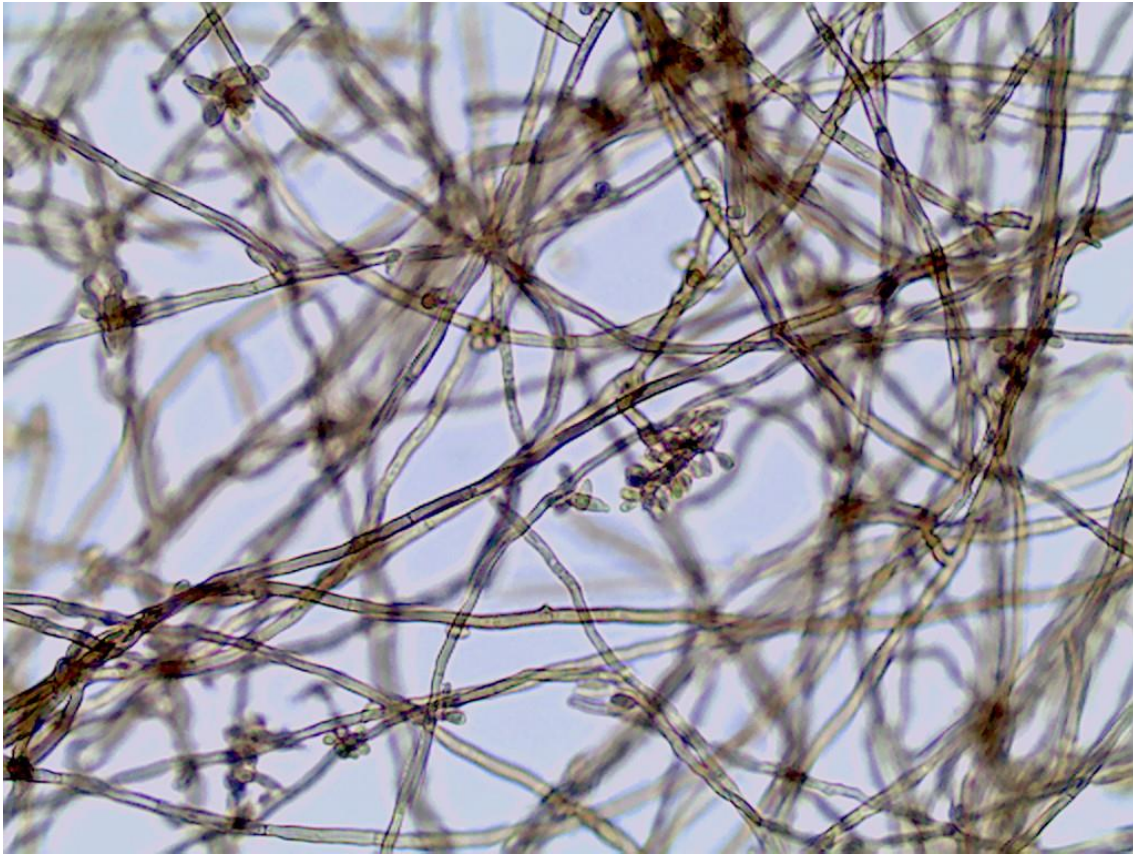
24



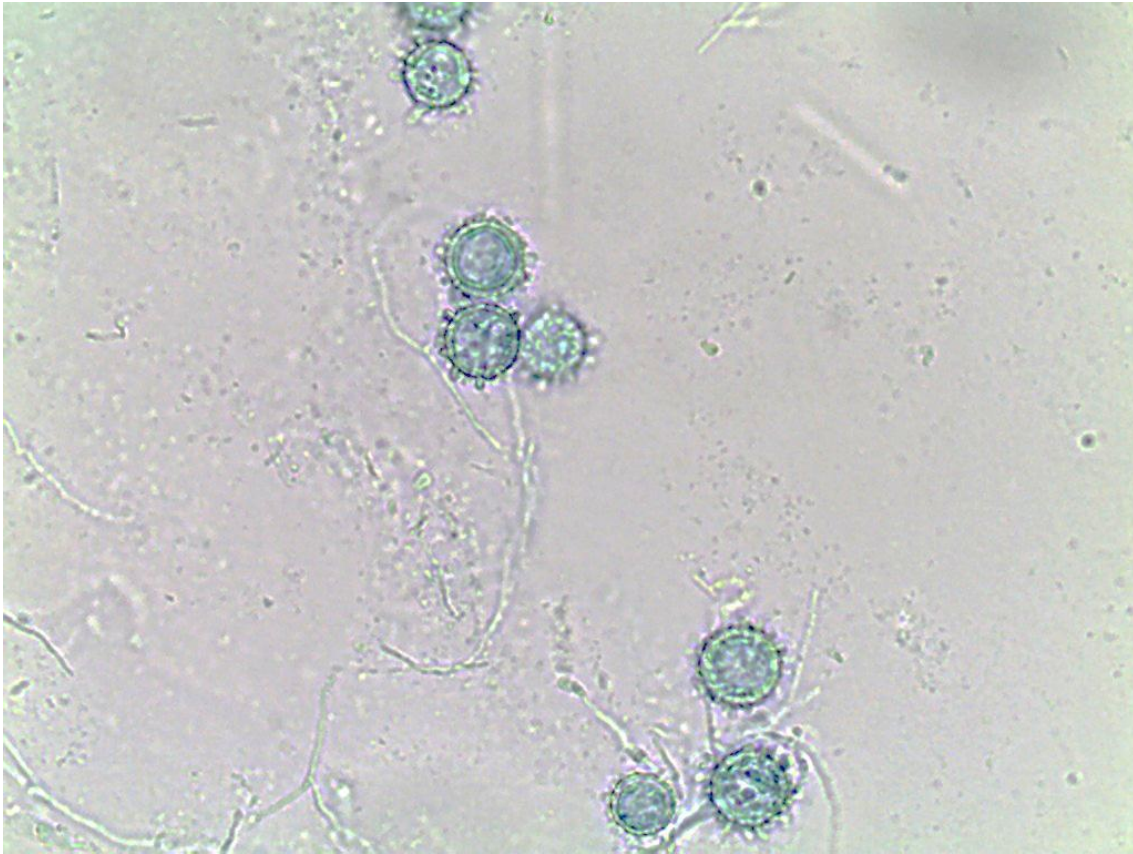
Lâmina 24: Exame direto de biópsia pele, 400x.



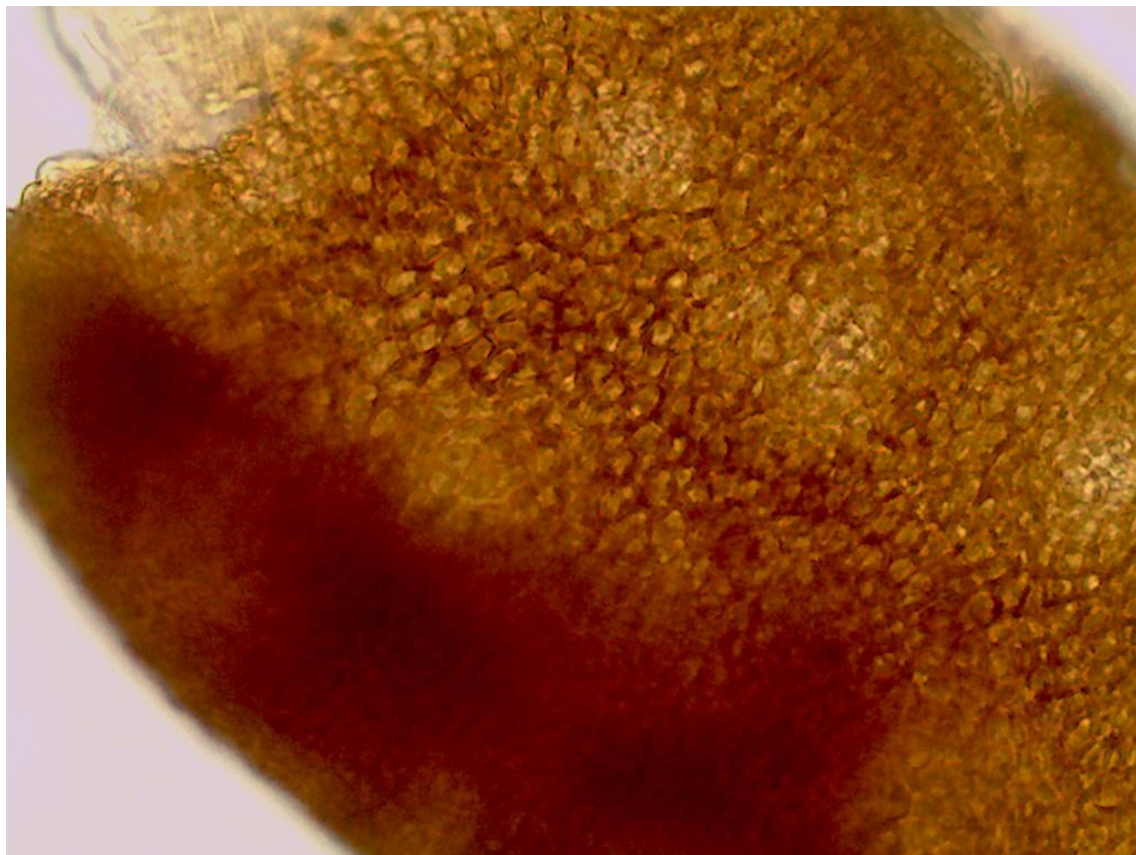
Lâmina 25: Micromorfologia de colônia de fungo demácio, 400x



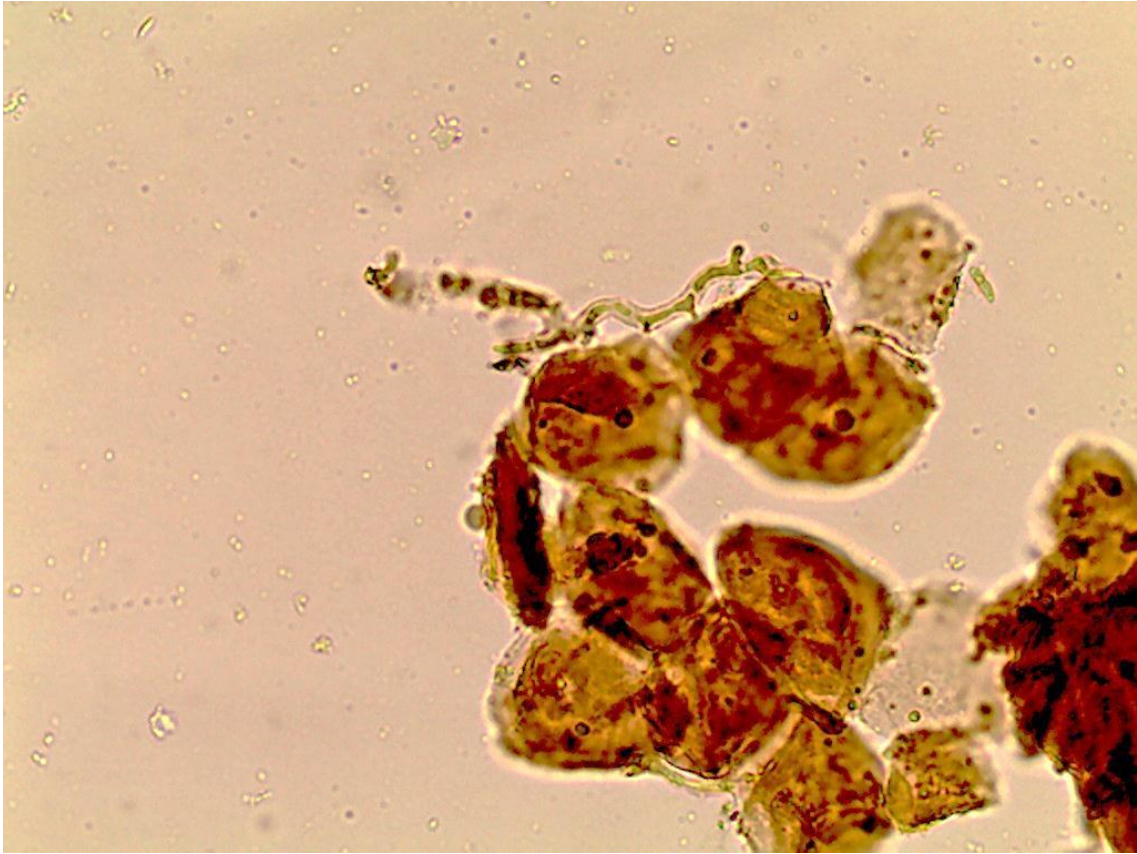Lâmina 26: Micromorfologia de colônia de fungo, 400x



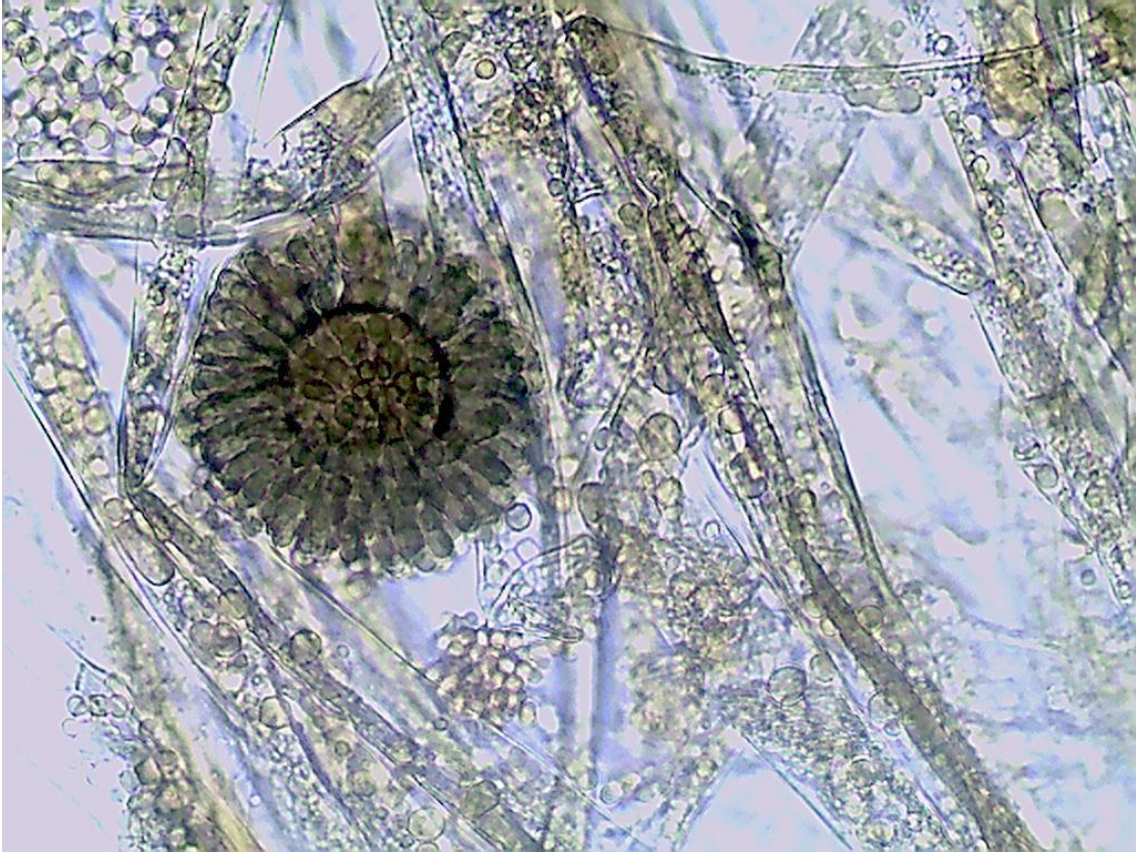Lâmina 27: Exame direto de pelo, 100x e 400x.



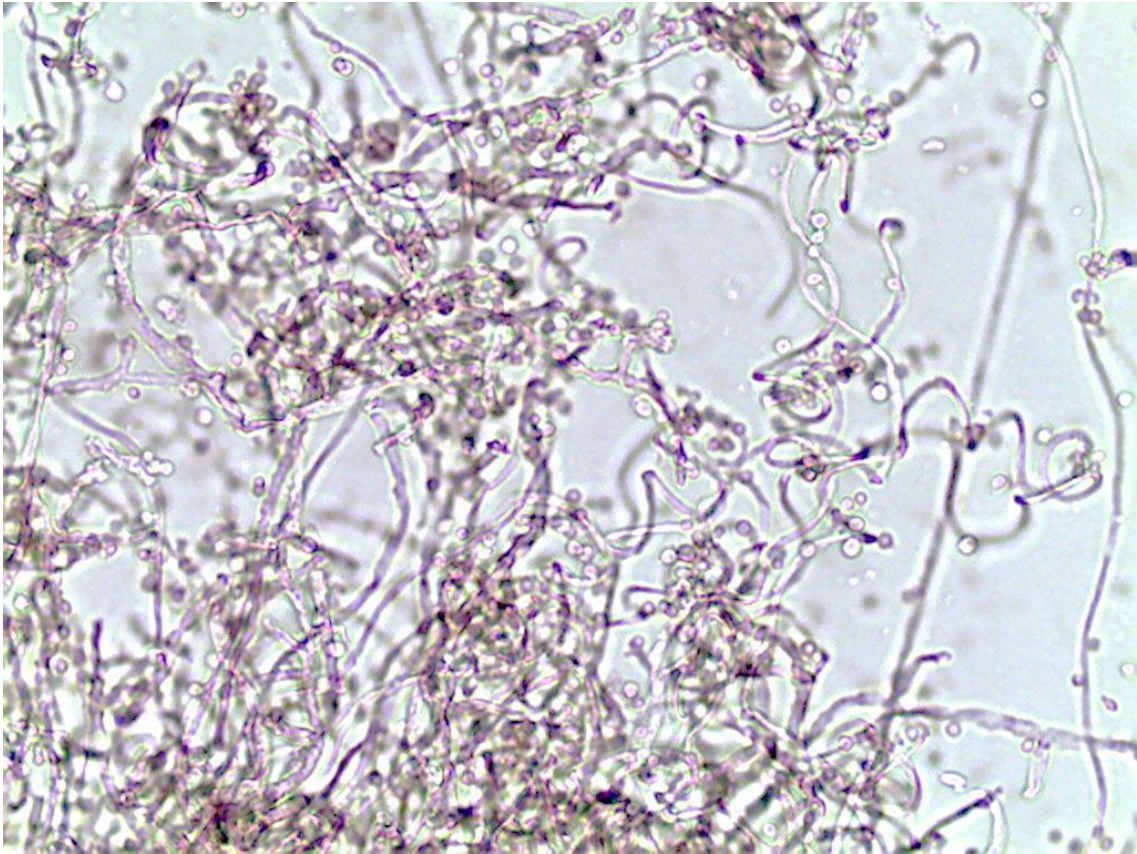
Lâmina 28: Exame direto de raspado cutâneo, 400x.



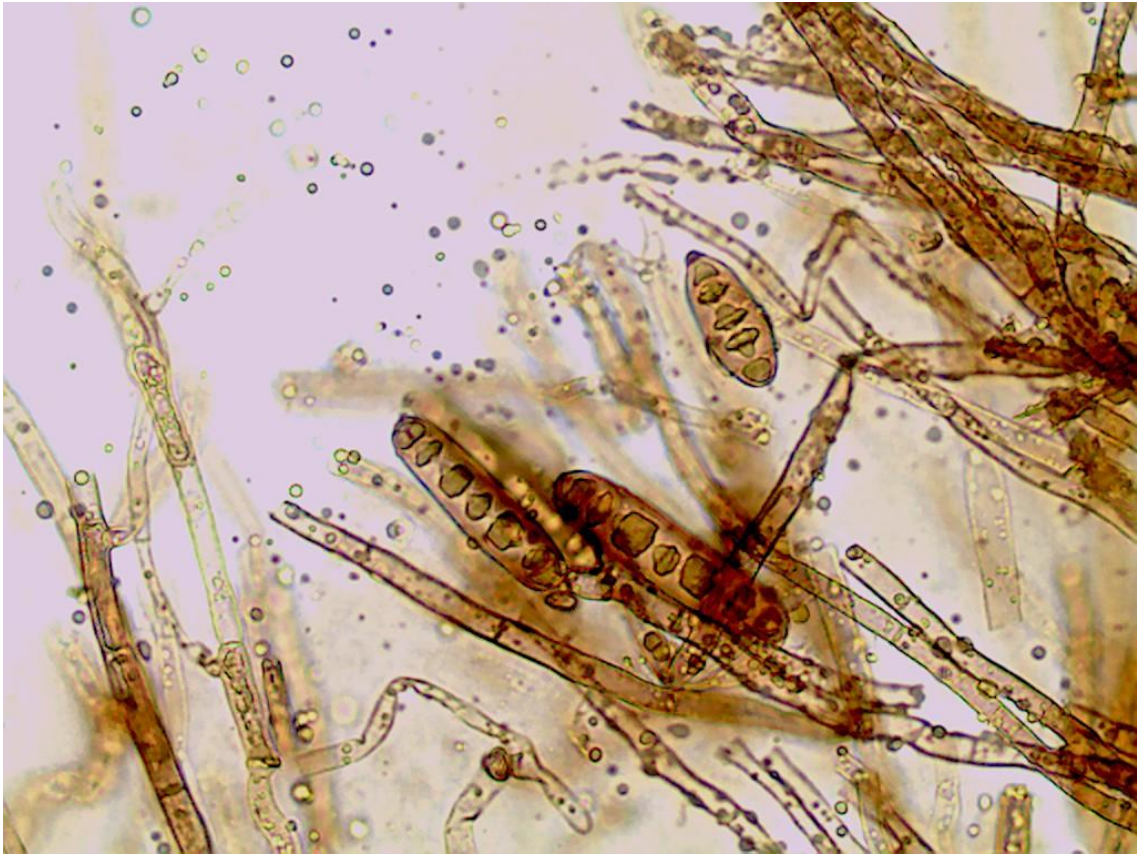Lâmina 29: Micromorfologia de colônia de fungo, 400x



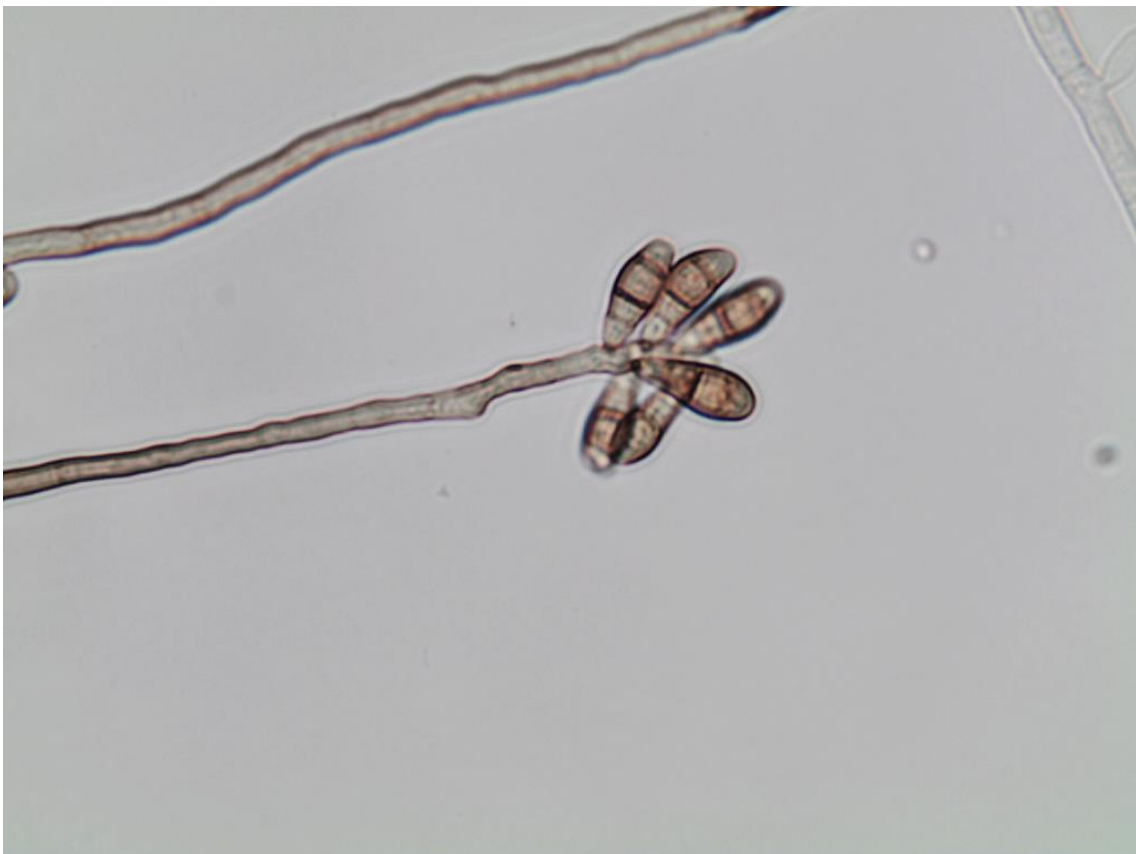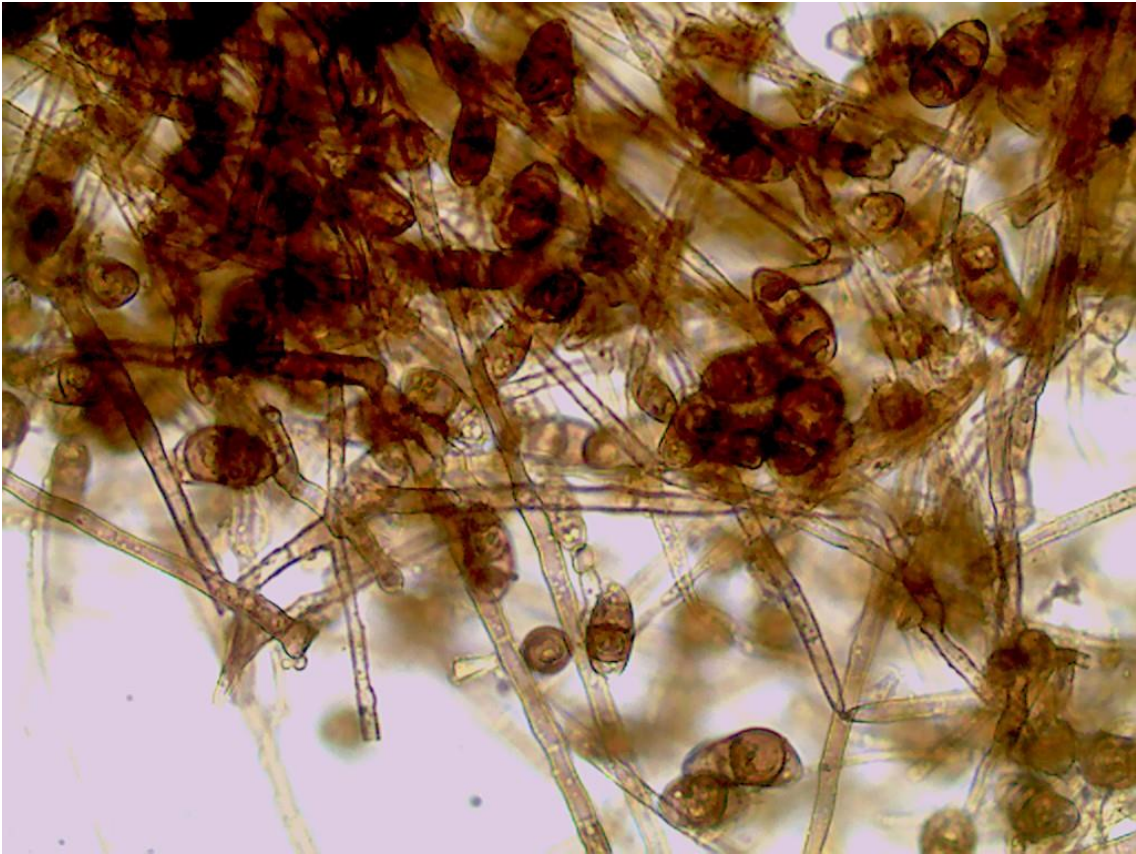
Lâmina 30: Micromorfologia de colônia de fungo, 400x



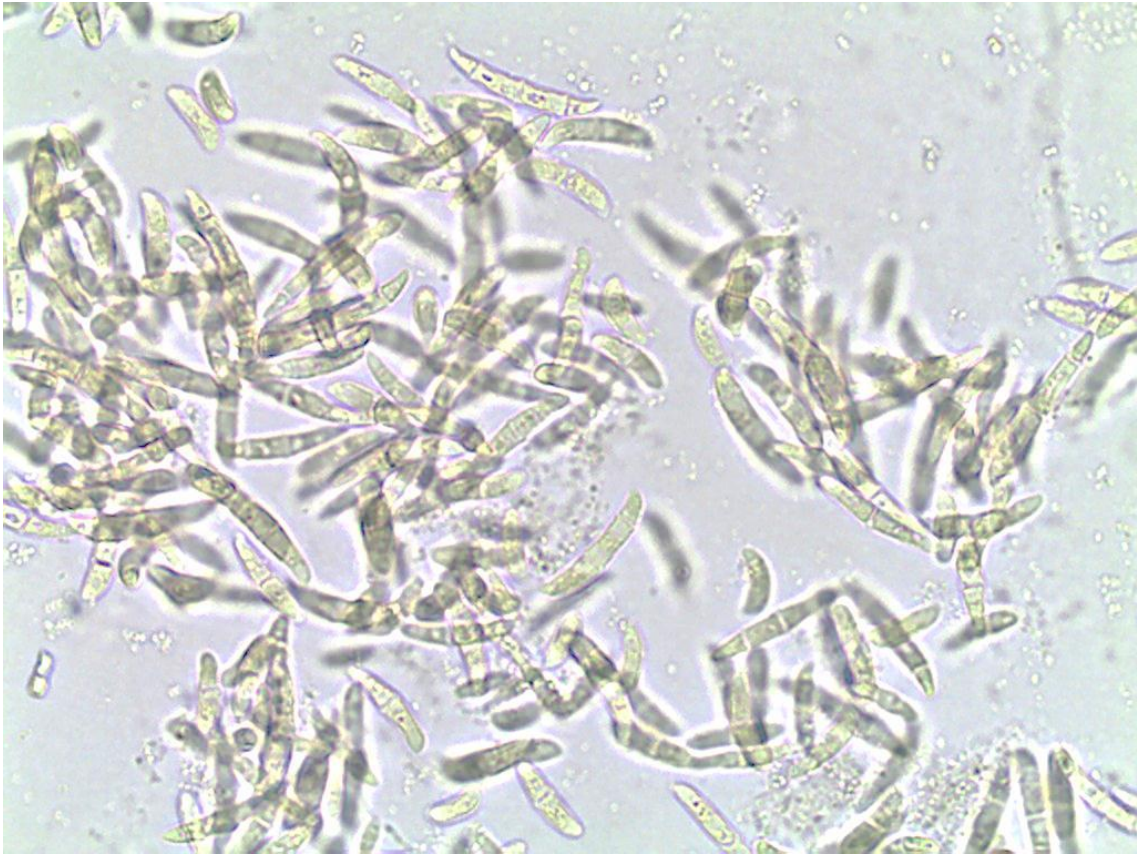Lâmina 31: Micromorfologia de colônia de fungo demácio, 400x.



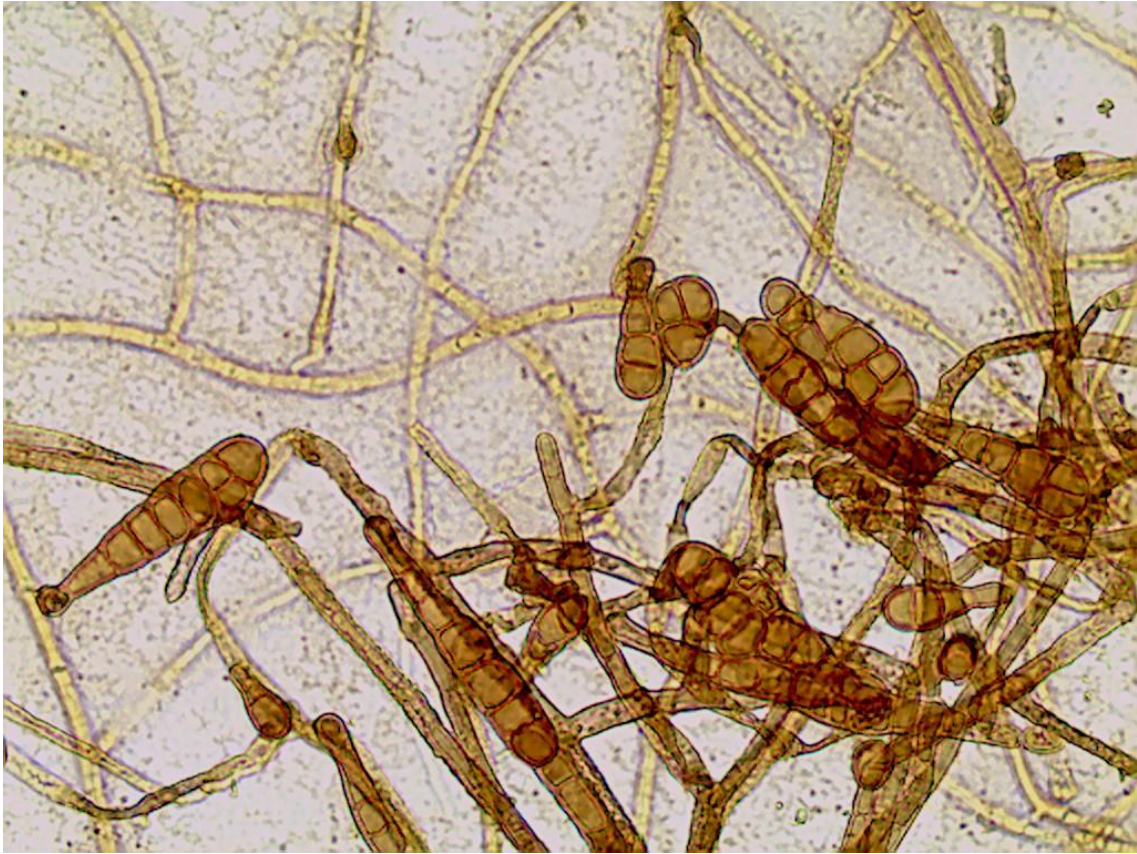Lâmina 32: Micromorfologia de colônia de fungo demácio, 400x.



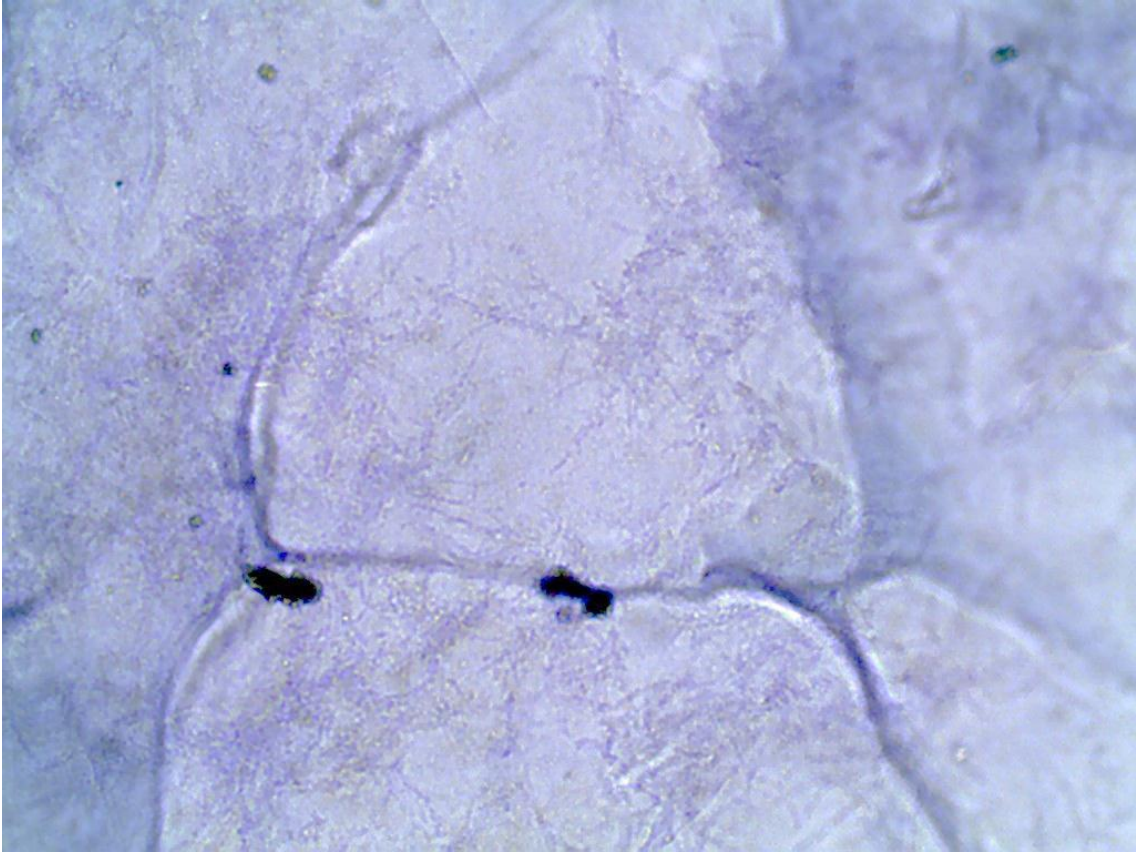
Lâmina 33: Micromorfologia de colônia de fungo, 400x.



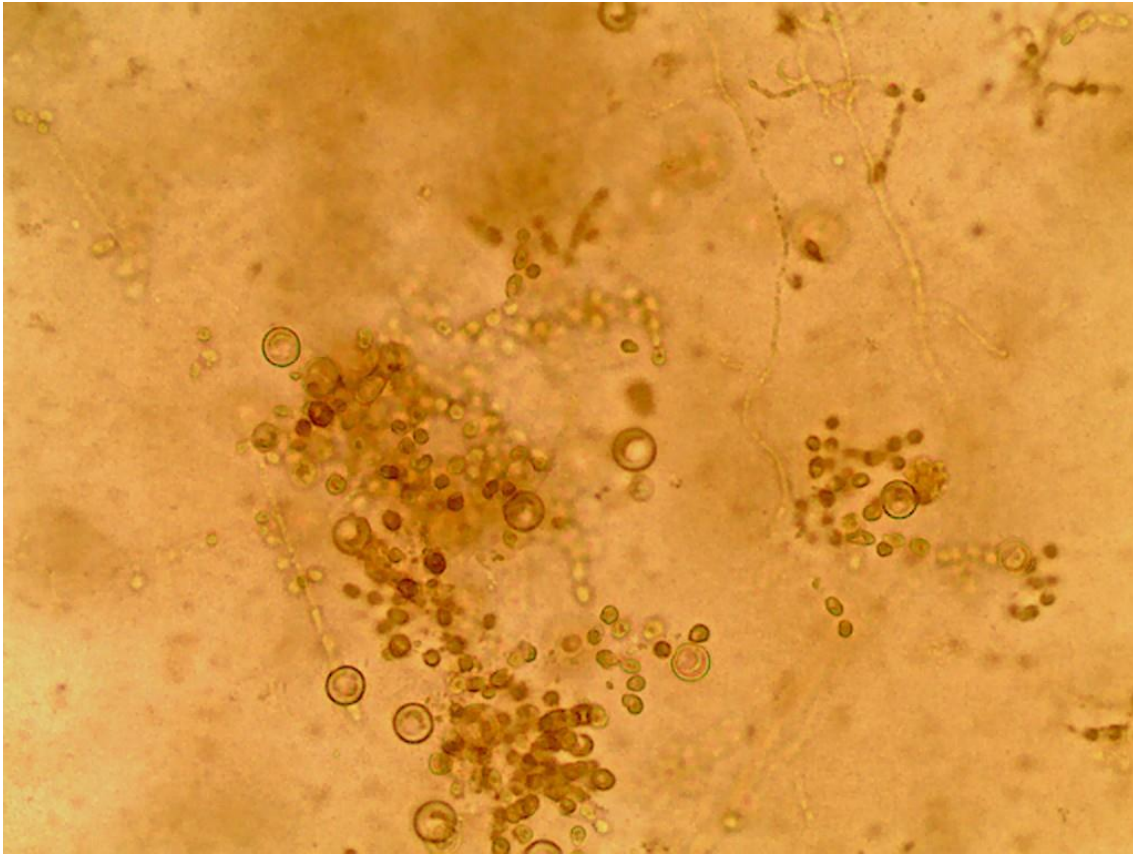
Lâmina 34: Micromorfologia de colônia de fungo demácio, 400x.



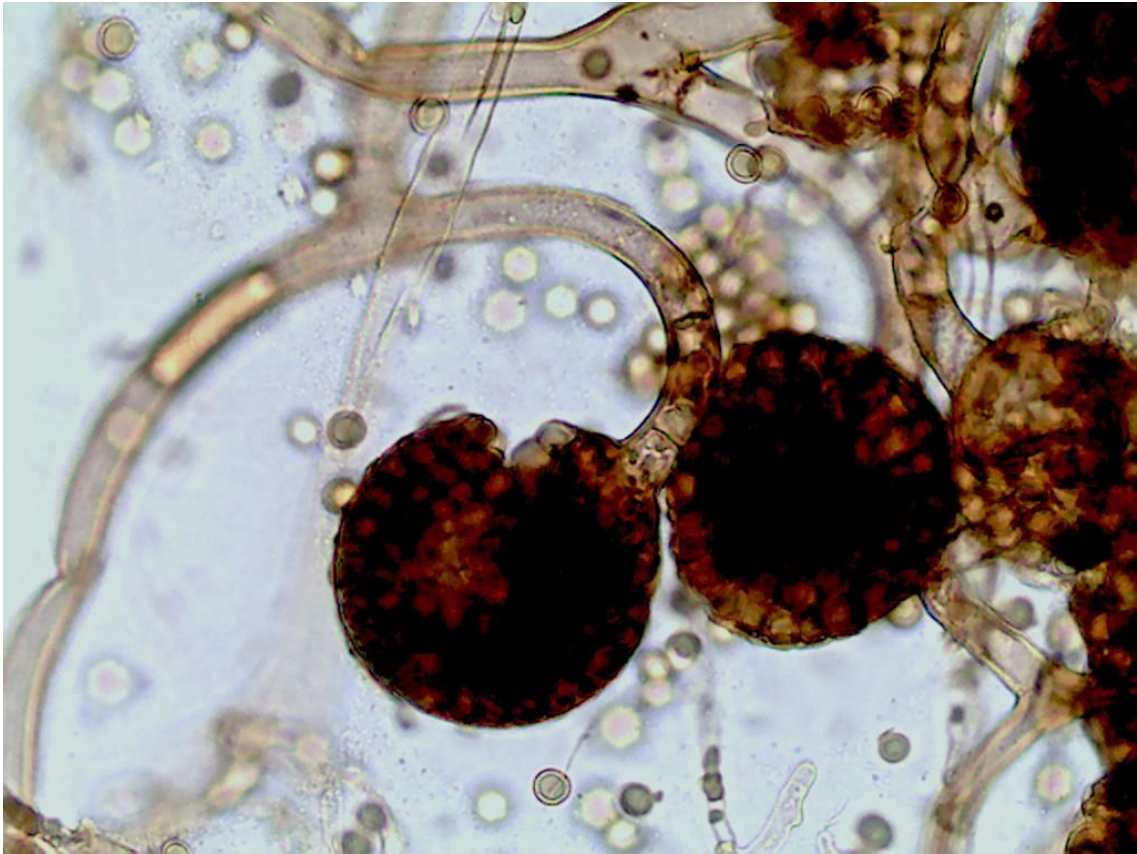
Lâmina 35: Exame direto de raspado cutâneo corado pelo Giemsa, 400x.



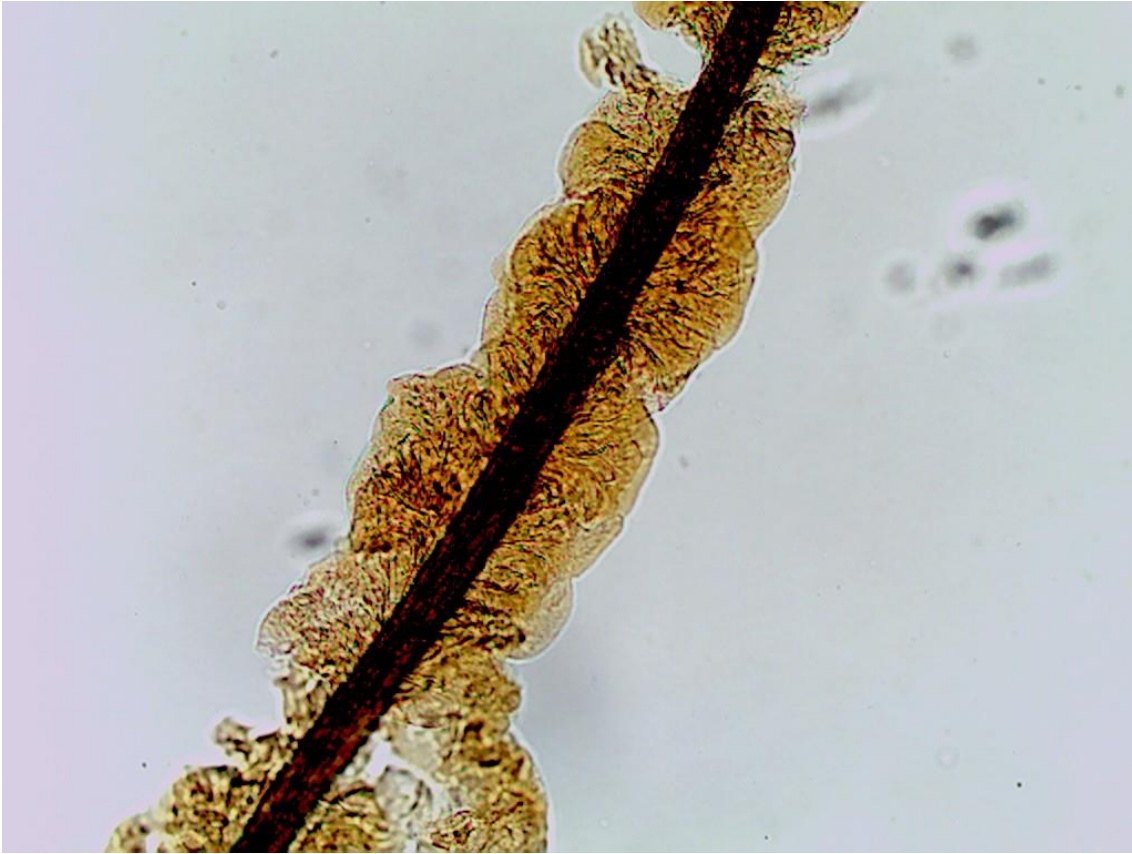Lâmina 36: Micromorfologia de colônia de fungo, 400x.



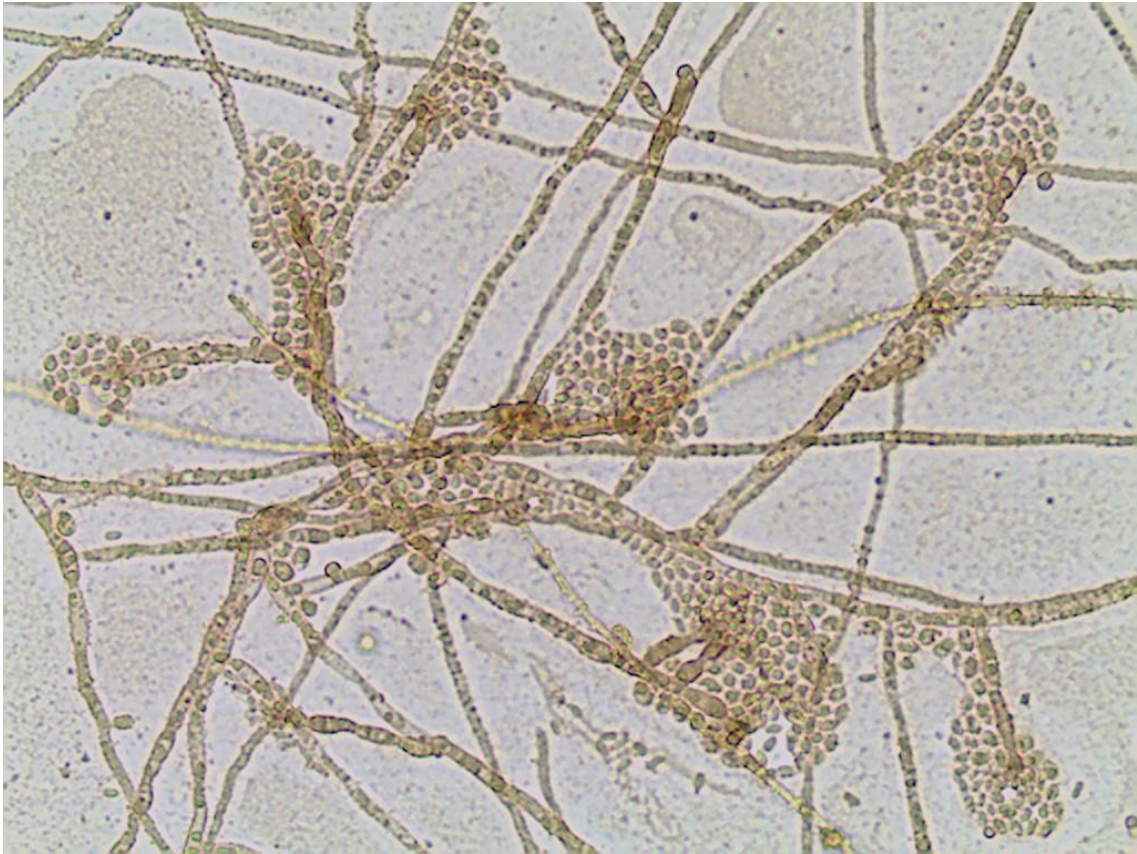
Lâmina 37: Micromorfologia de colônia de fungo, 400x.



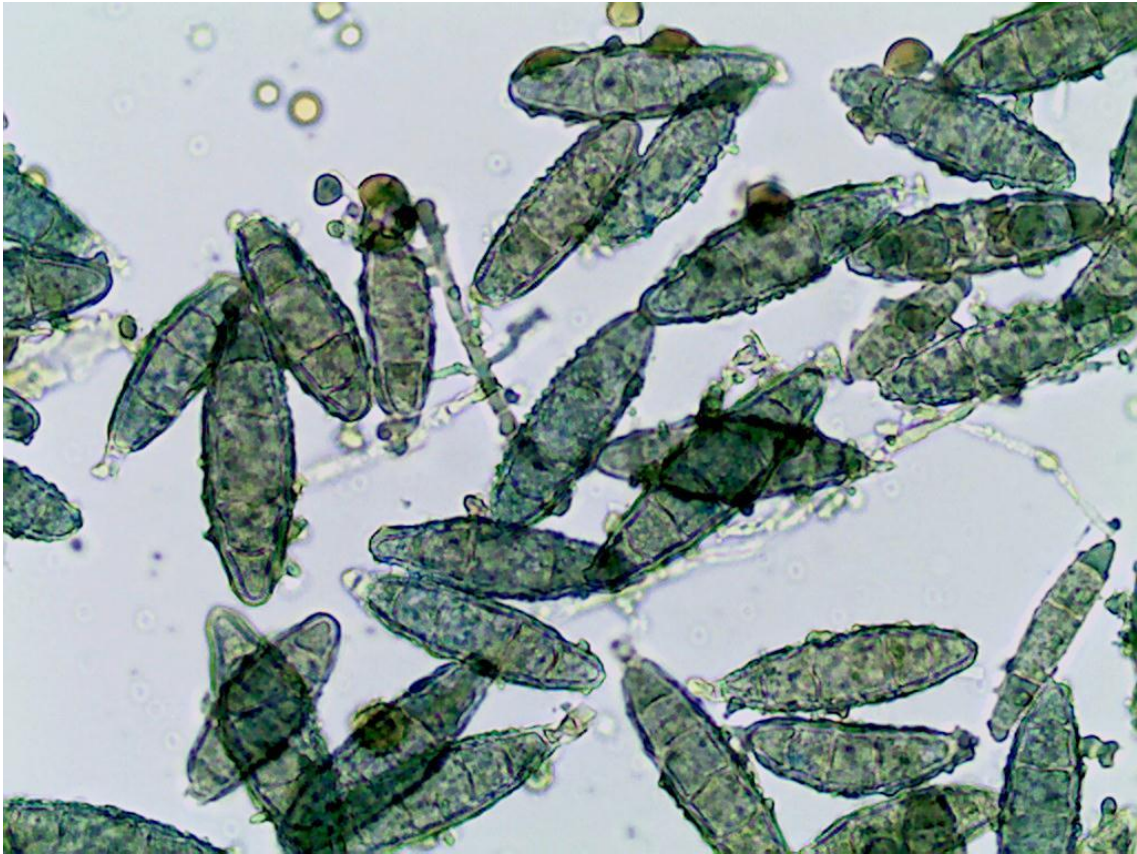Lâmina 38: Exame direto de pelo genital, 100x.



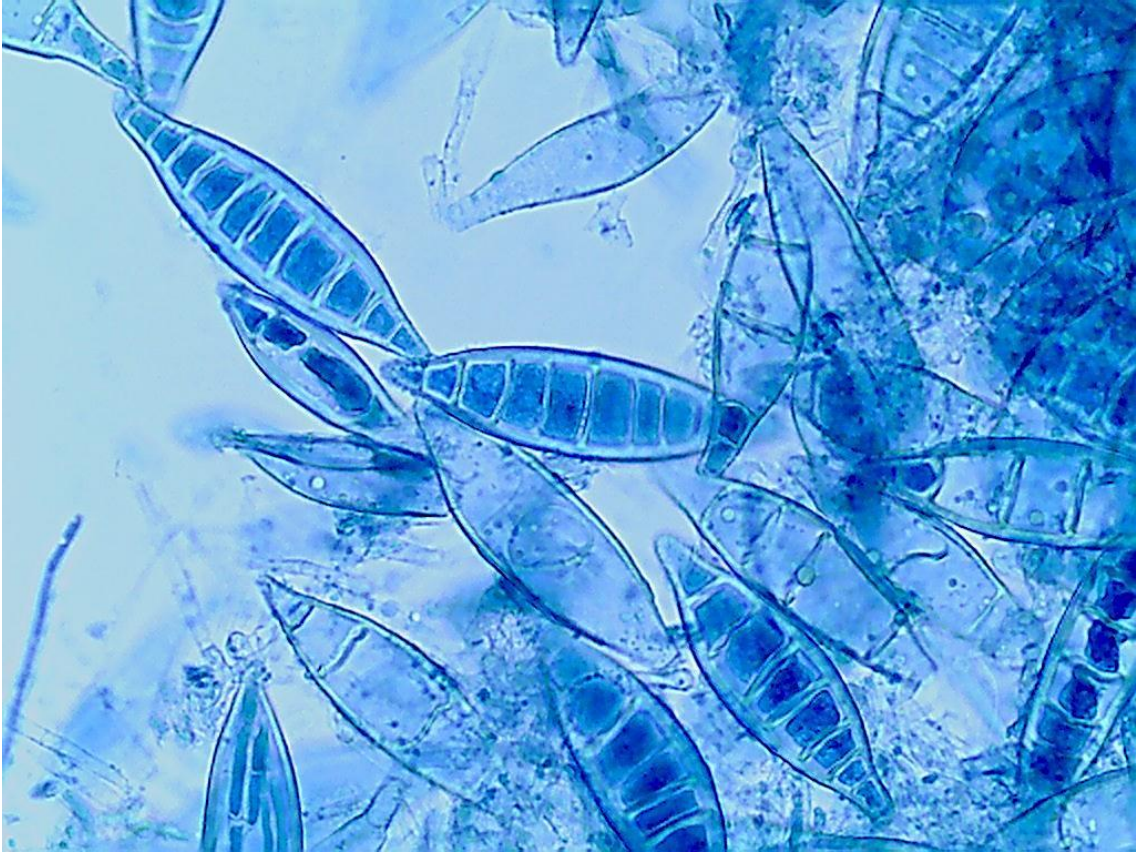Lâmina 39: Micromorfologia de colônia de fungo, 400x.



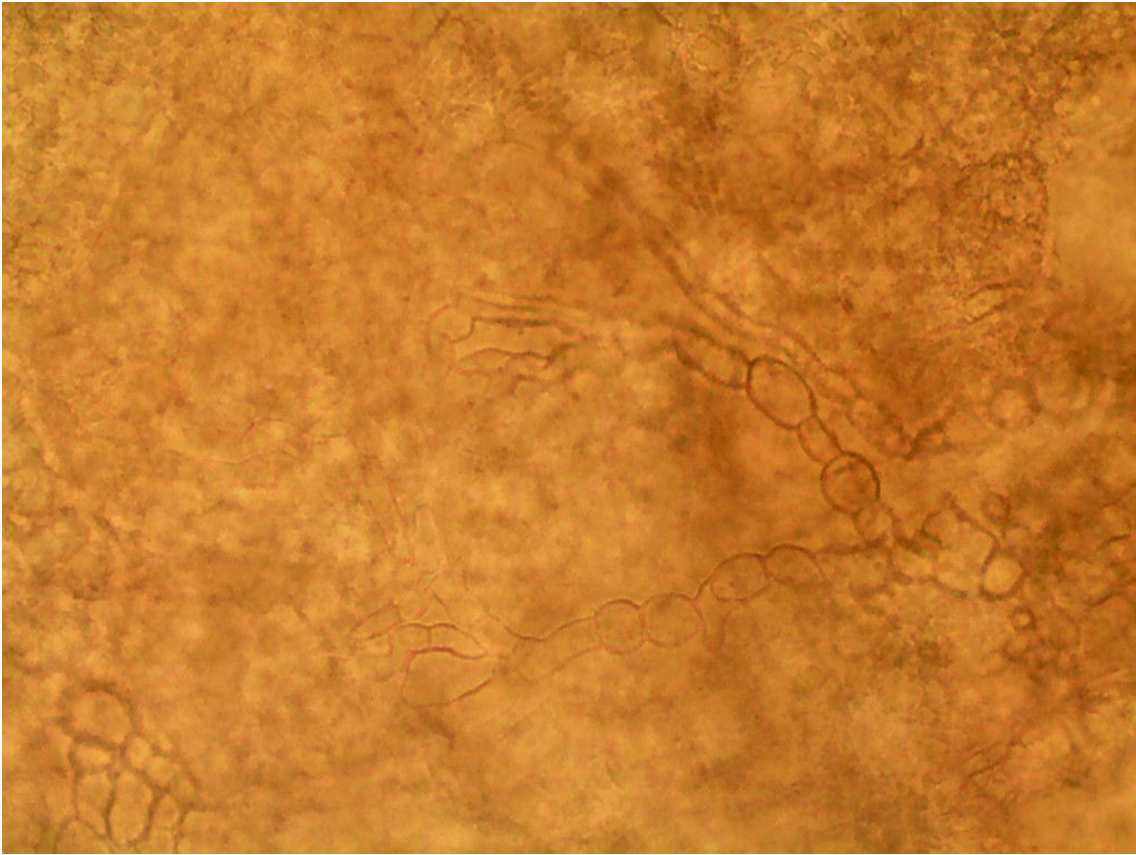
Lâmina 40: Micromorfologia de colônia de fungo, 400x.



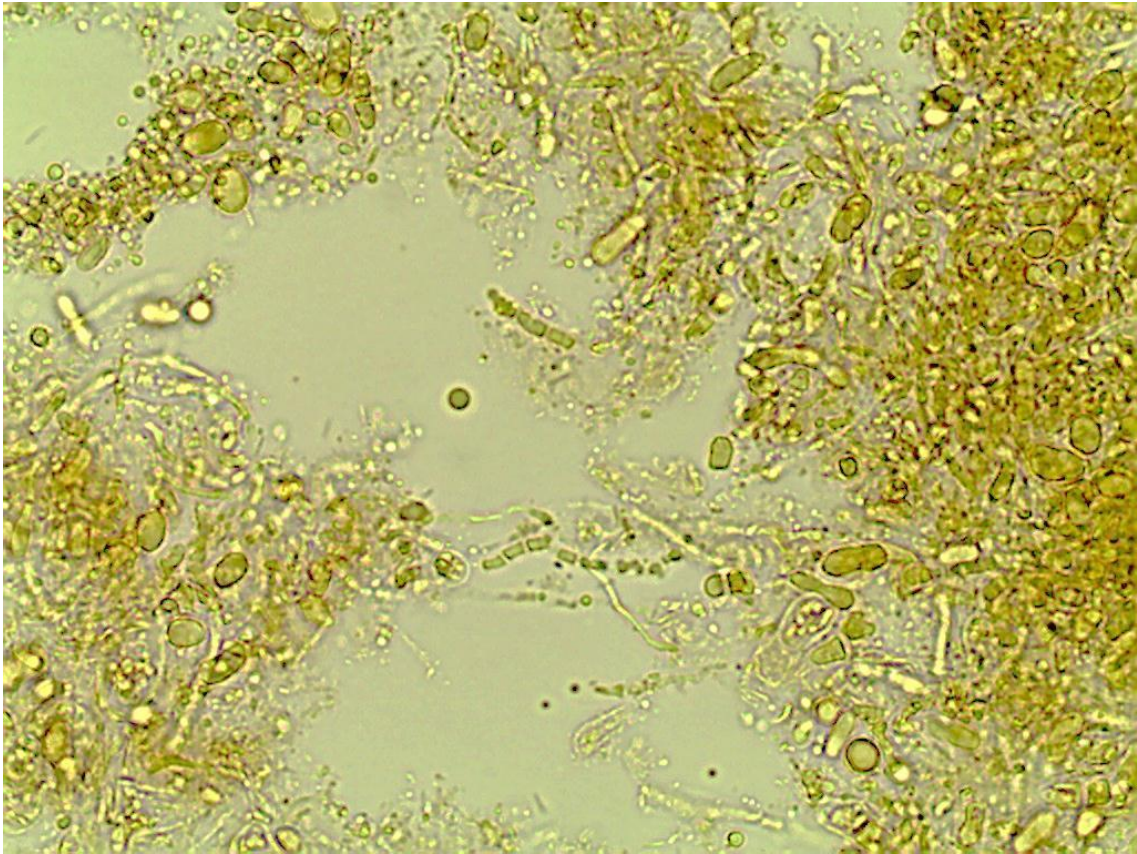
Lâmina 41: Micromorfologia de colônia de fungo, 400x.



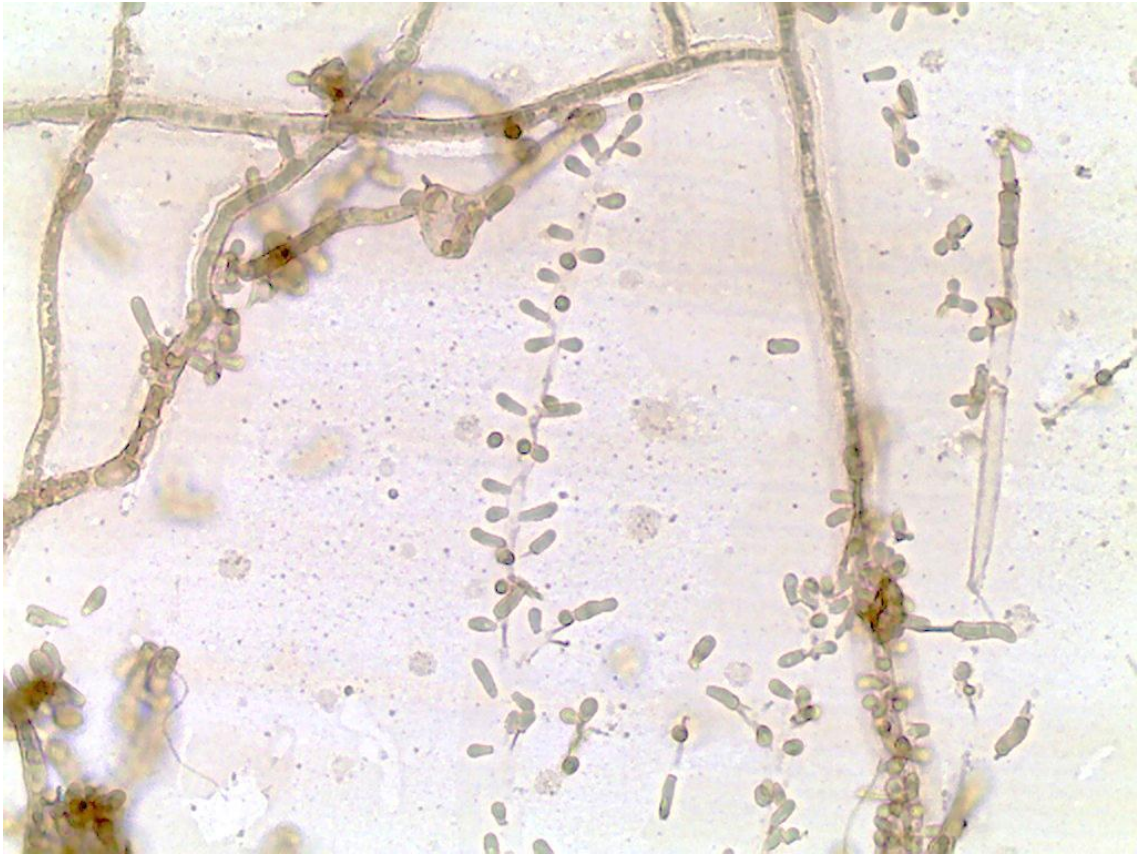
Lâmina 42: Exame direto de biópsia lesão cística, 400x, isolado fungo demácio.



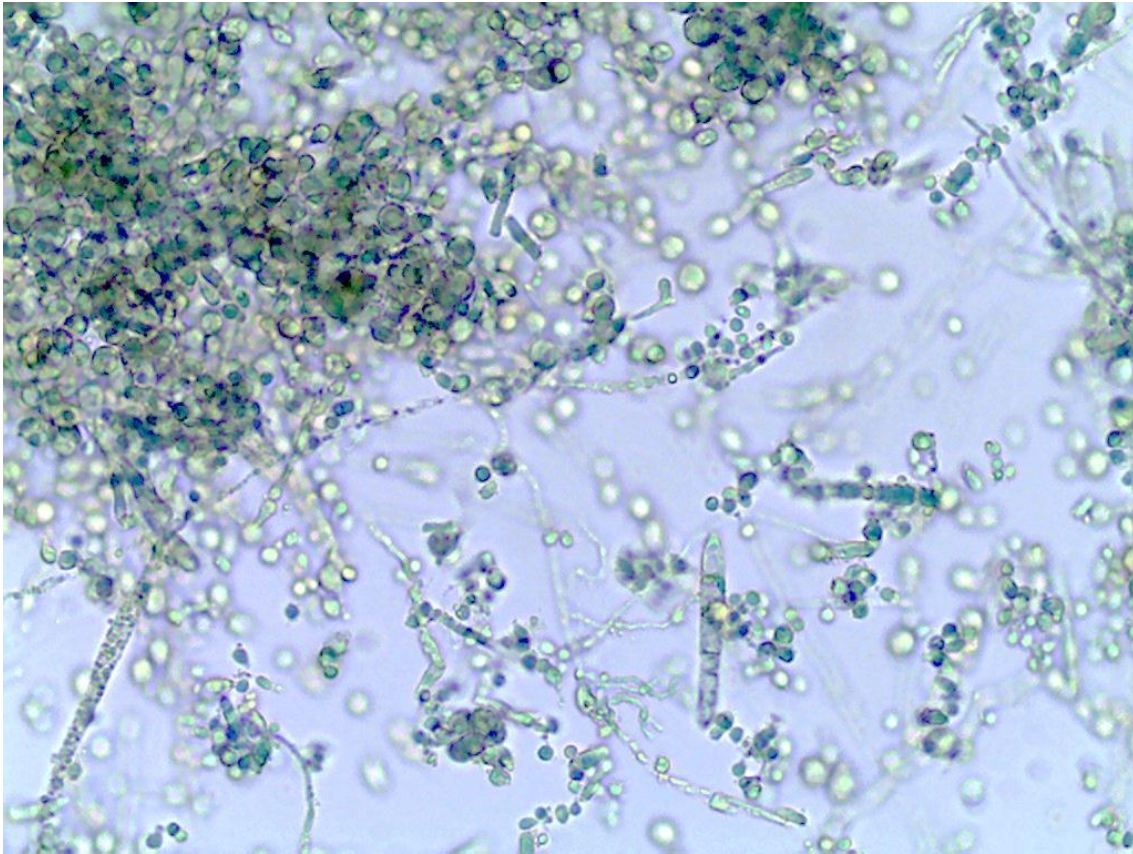
Lâmina 43: Micromorfologia de colônia de fungo, 400x.



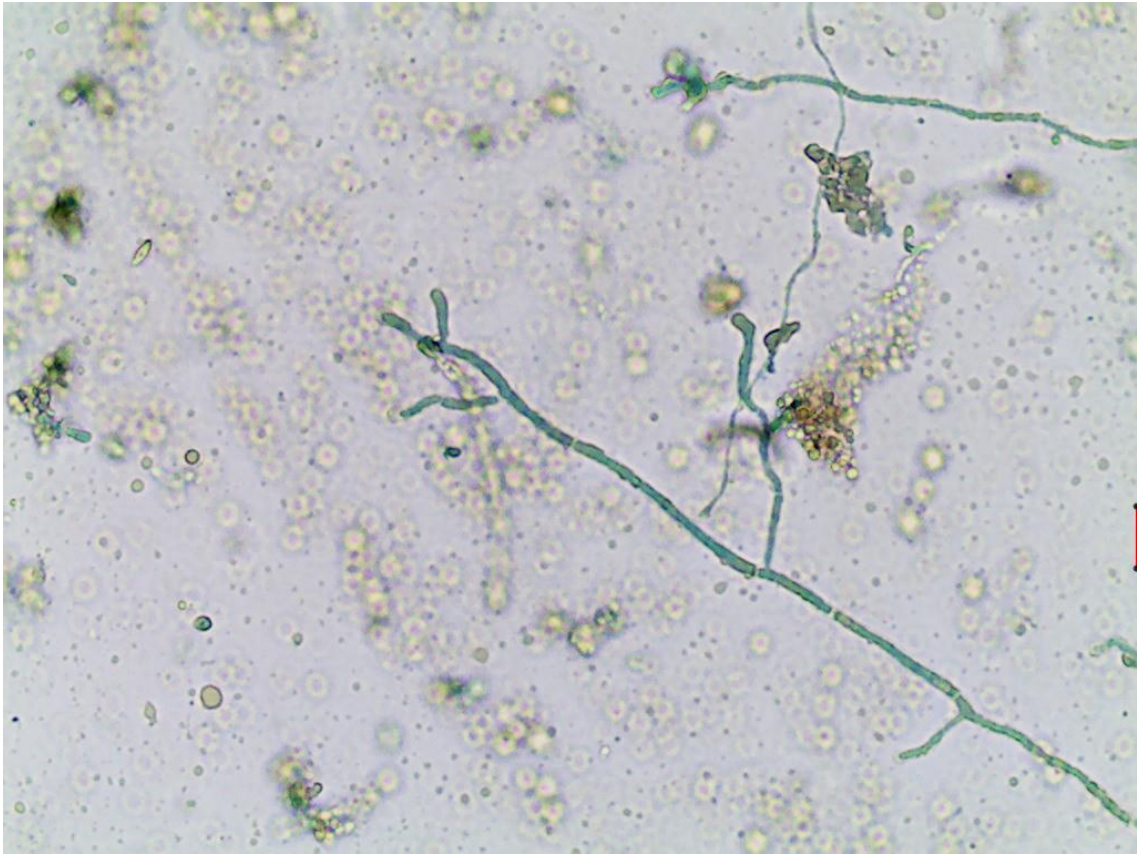
Lâmina 44: Micromorfologia de colônia de fungo, 400x.



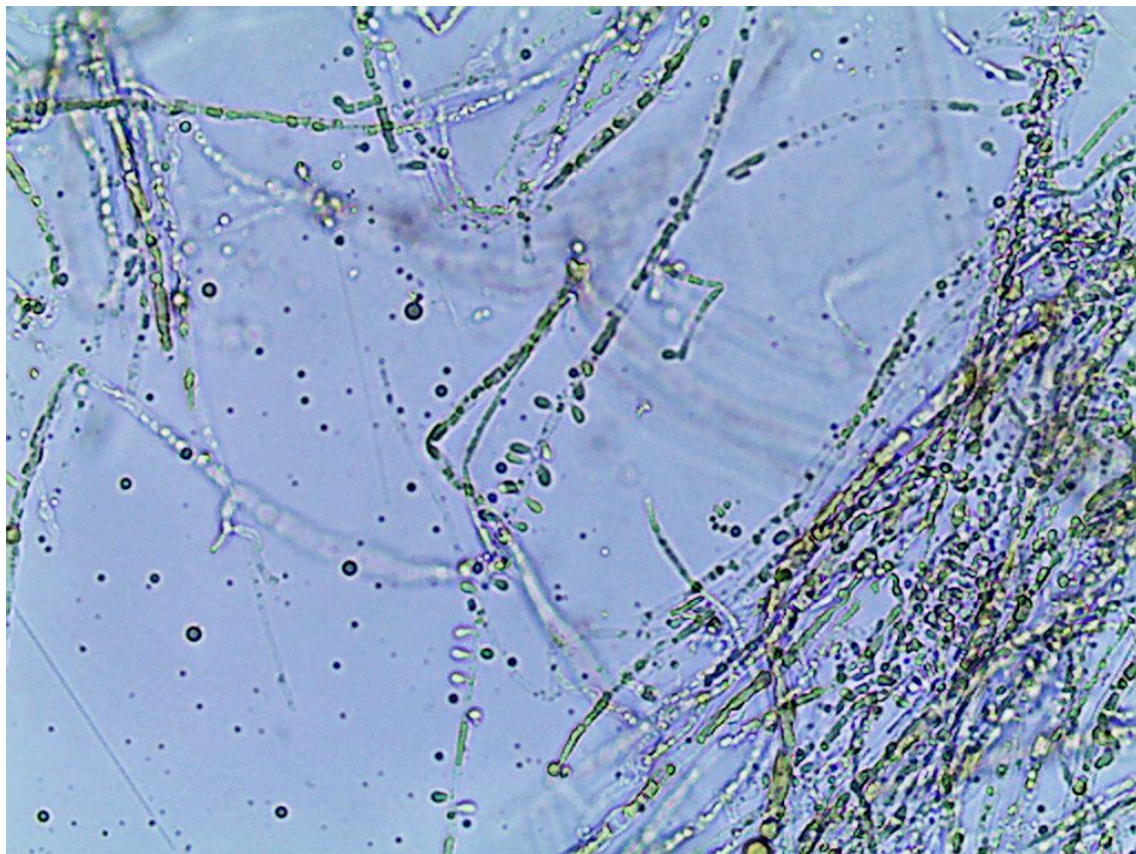
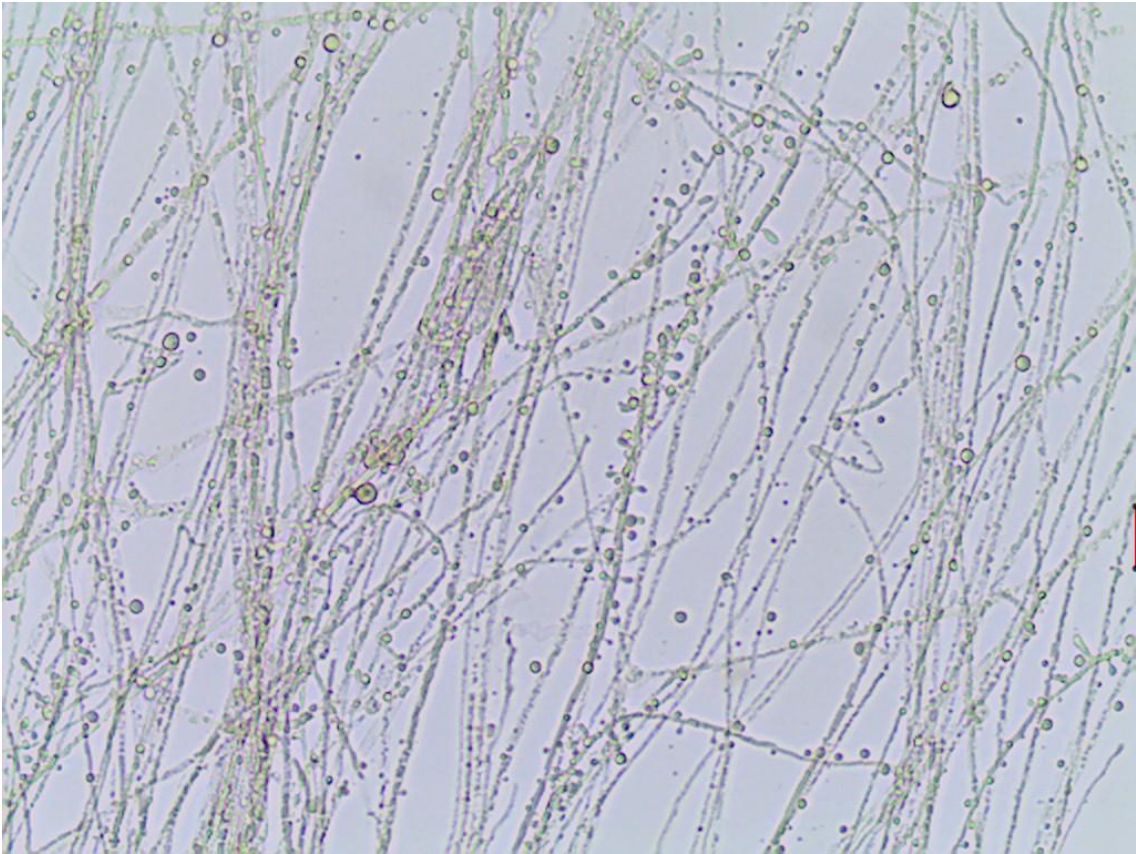
Lâmina 45: Micromorfologia de colônia de fungo, 400x.



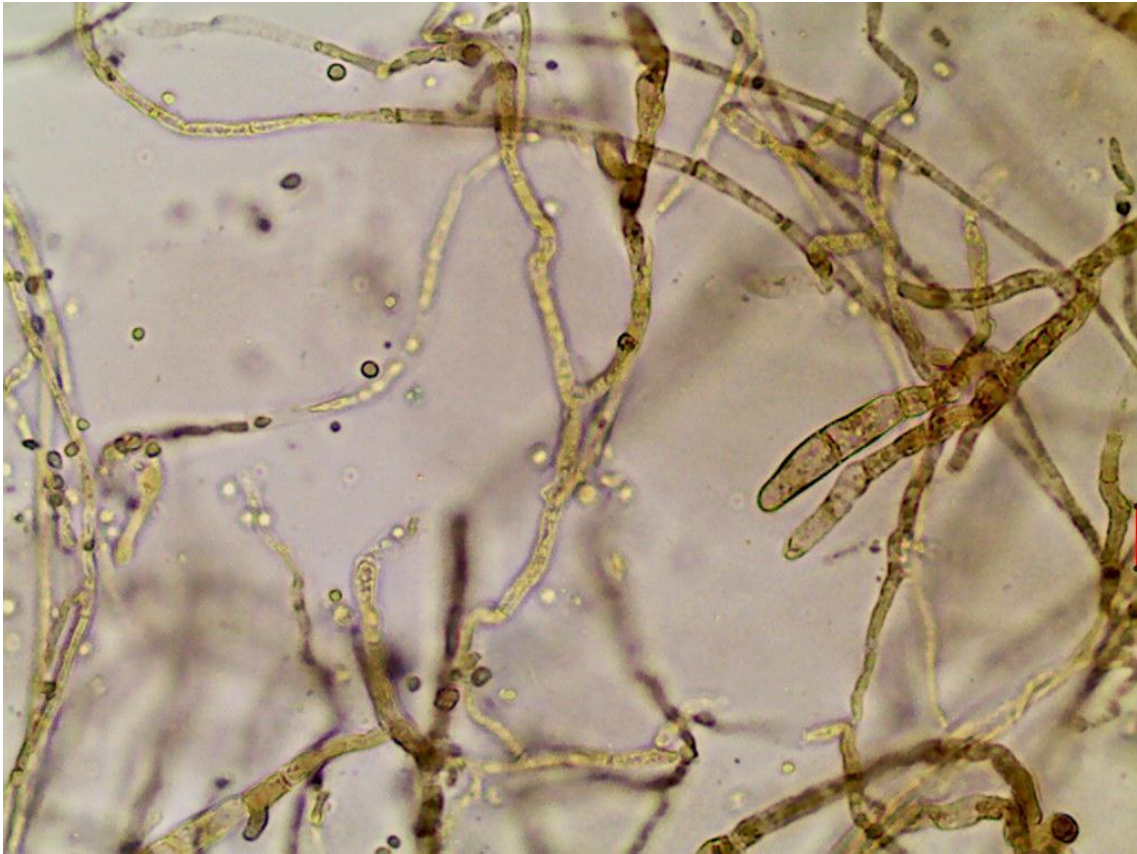
Lâmina 46: Micromorfologia de colônia de fungo, 400x.



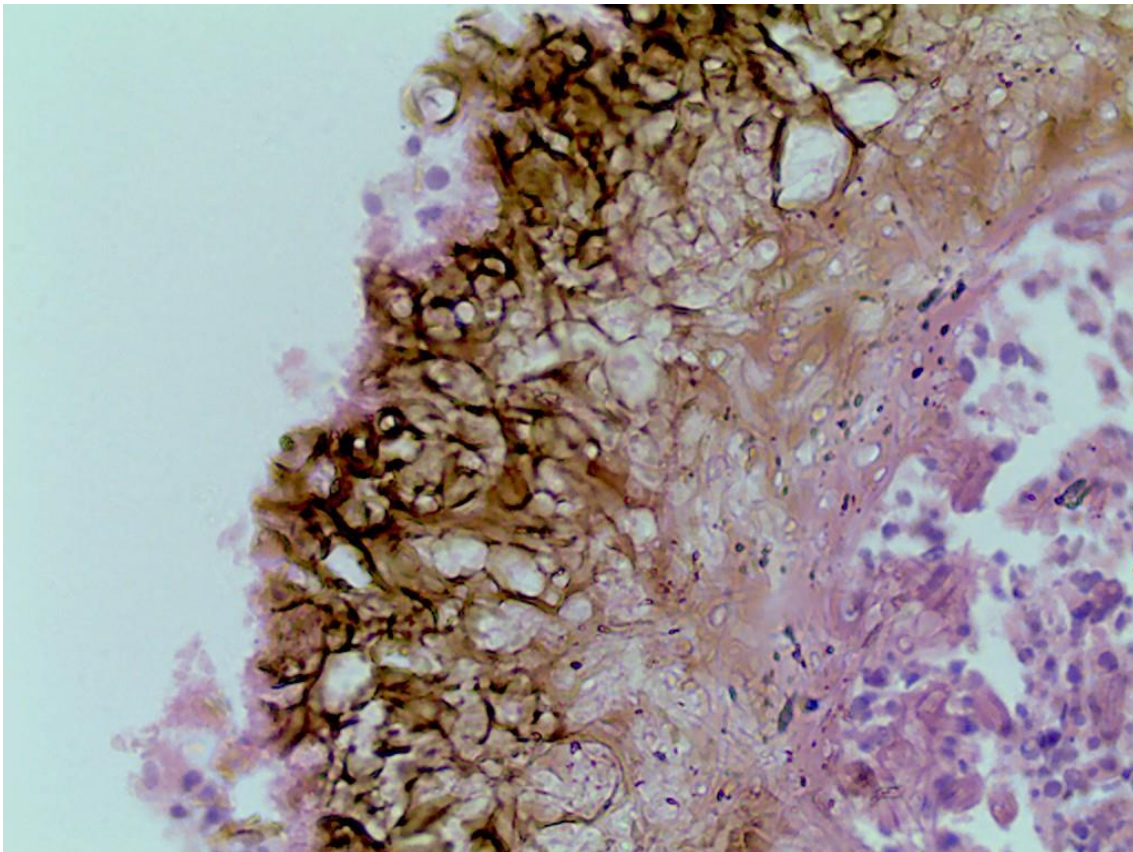
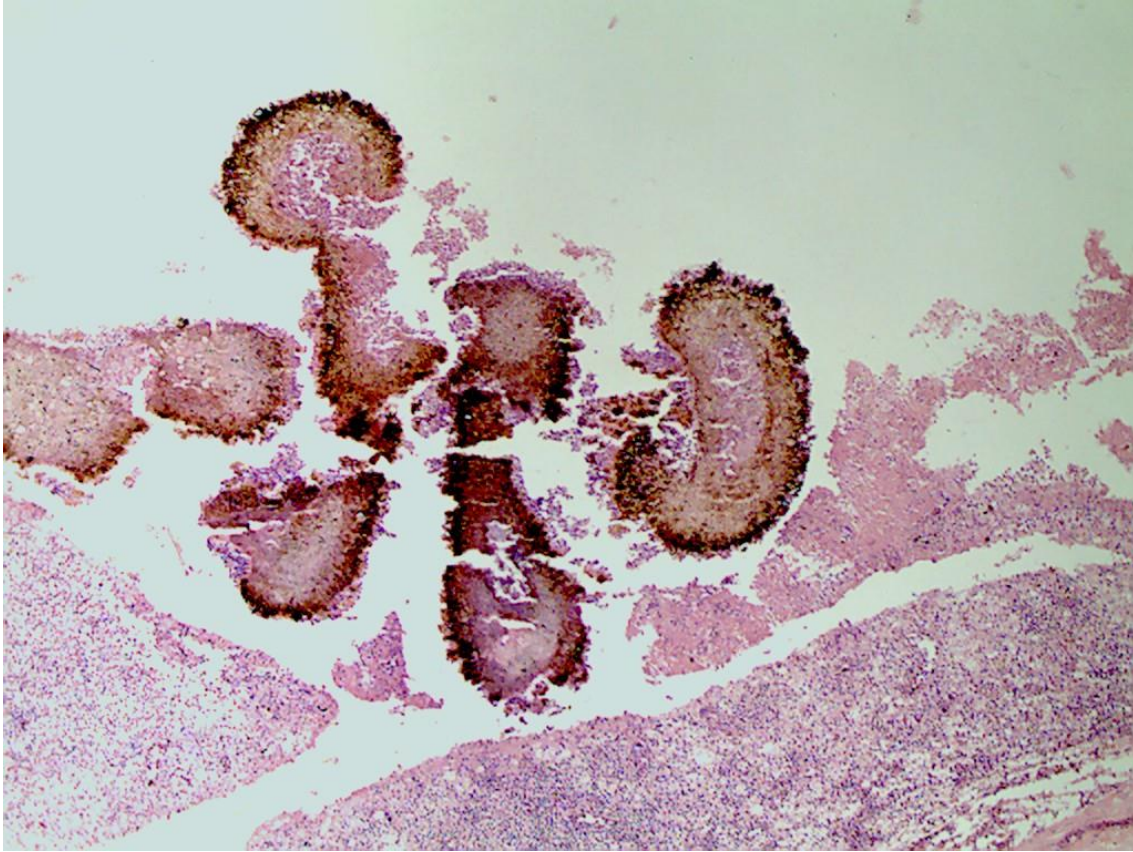
Lâmina 47: Micromorfologia de colônia de fungo, 400x.



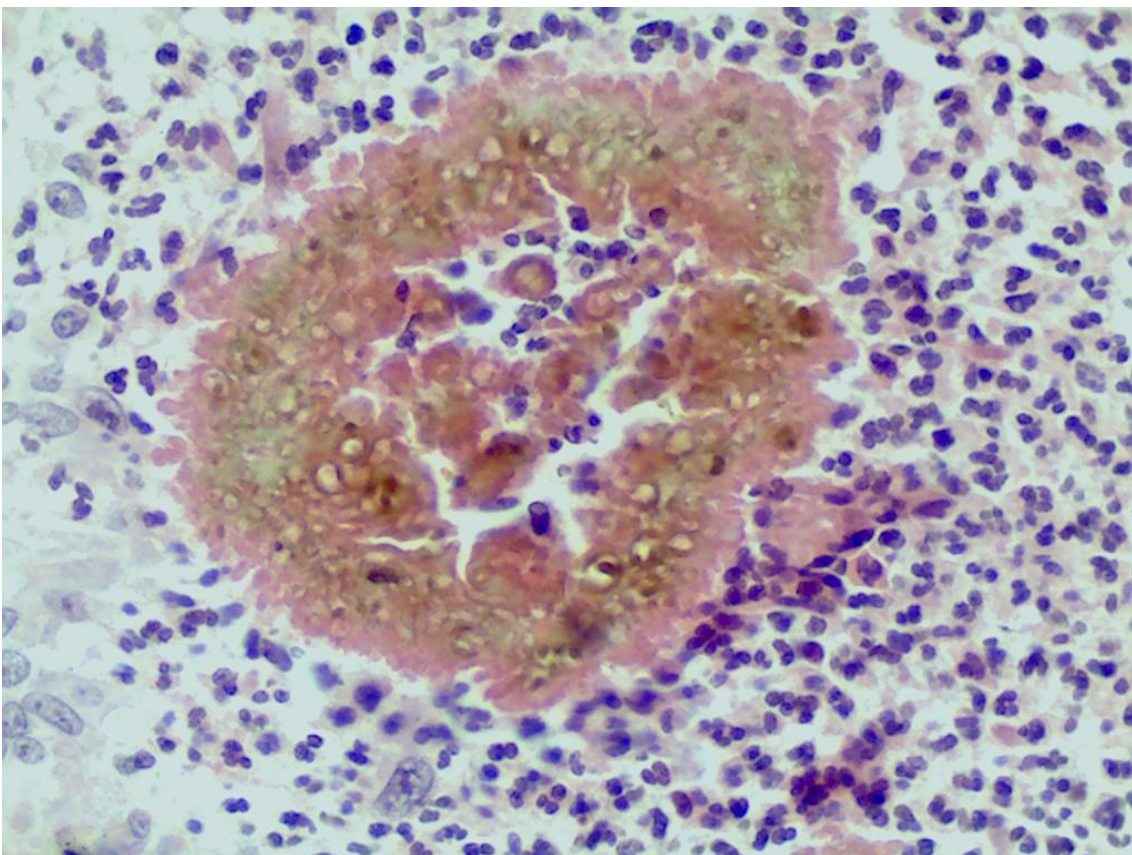
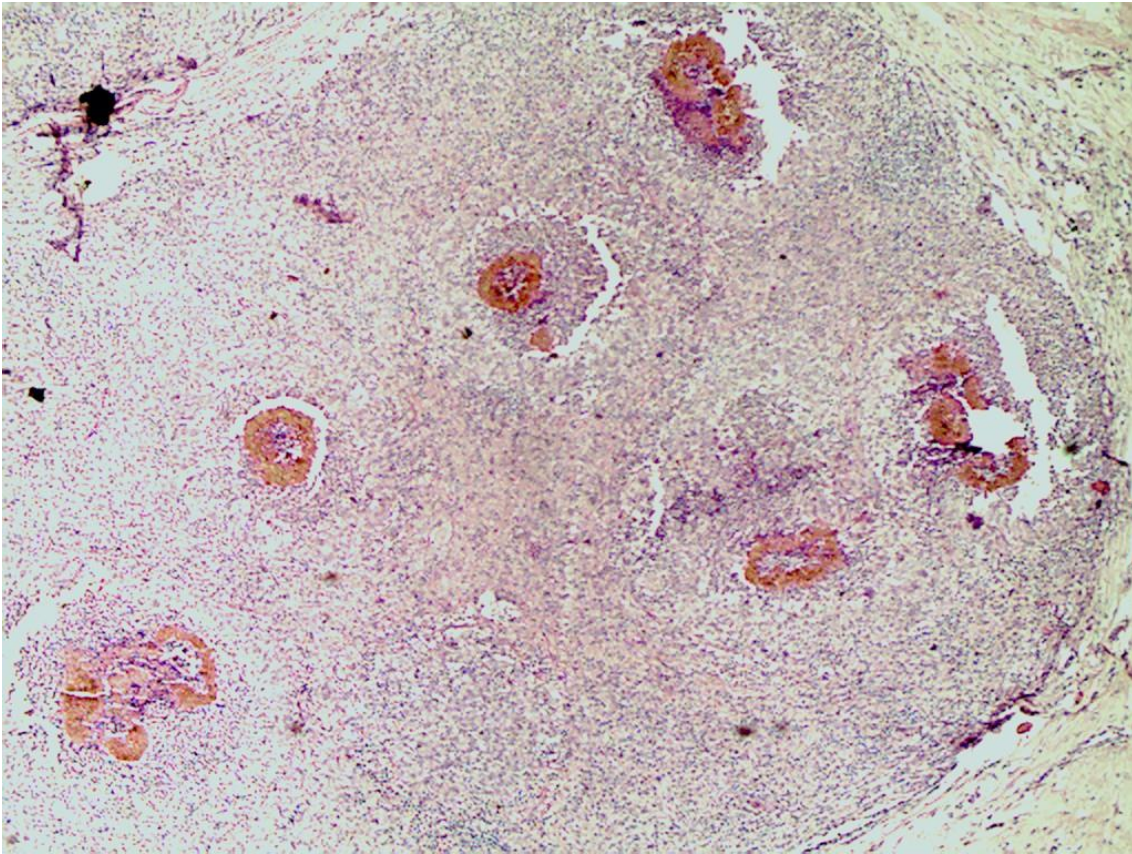
Lâmina 48: Micromorfologia de colônia de fungo, 400x.



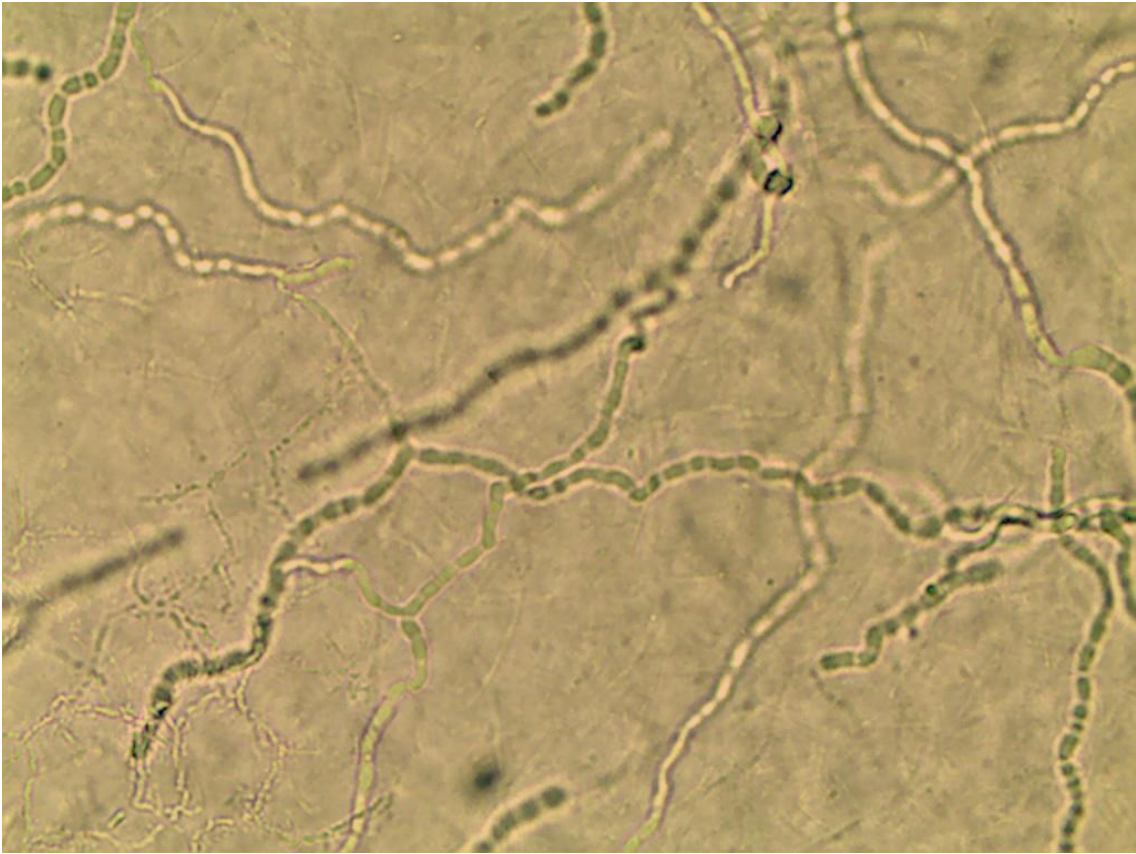
Lâmina 49: Exame direto de biópsia nódulo no pé direito corado pelo HE, 40x e 400x.



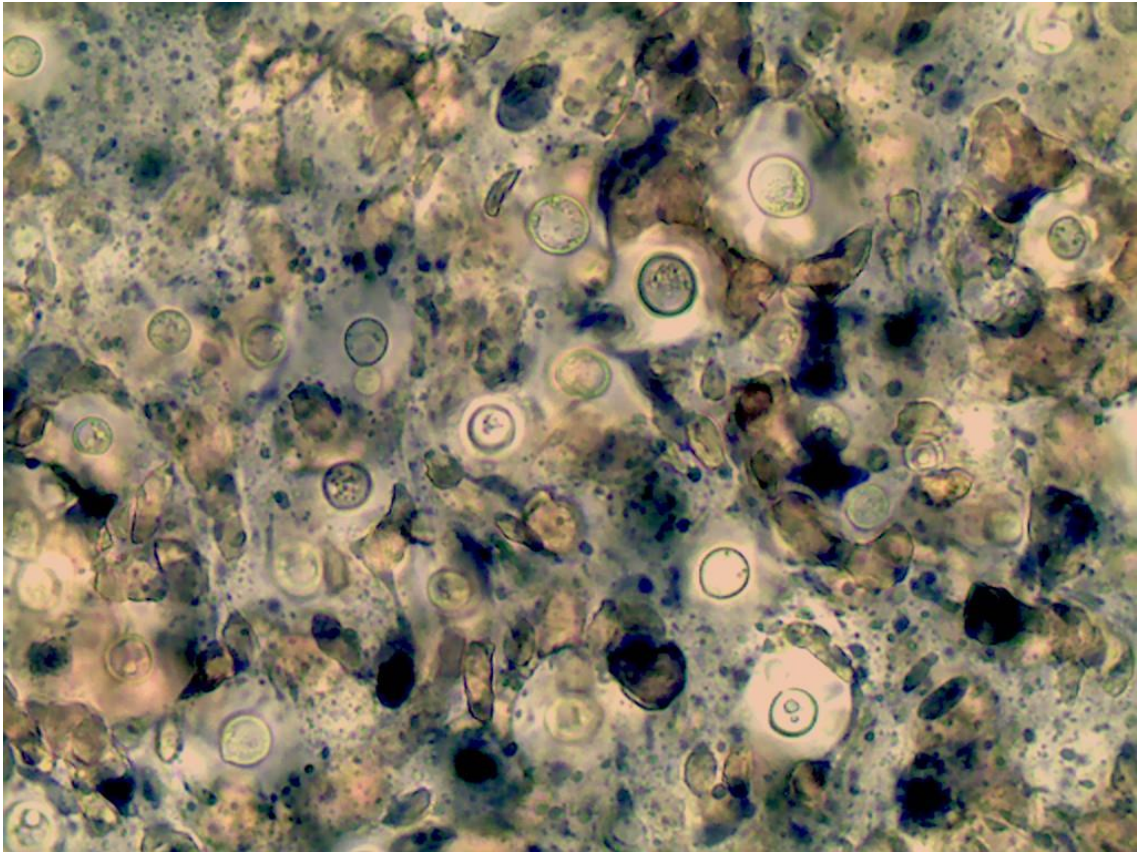
Lâmina 50: Exame direto de biópsia nódulo no pé direito corado pelo HE, 40x e 400x.



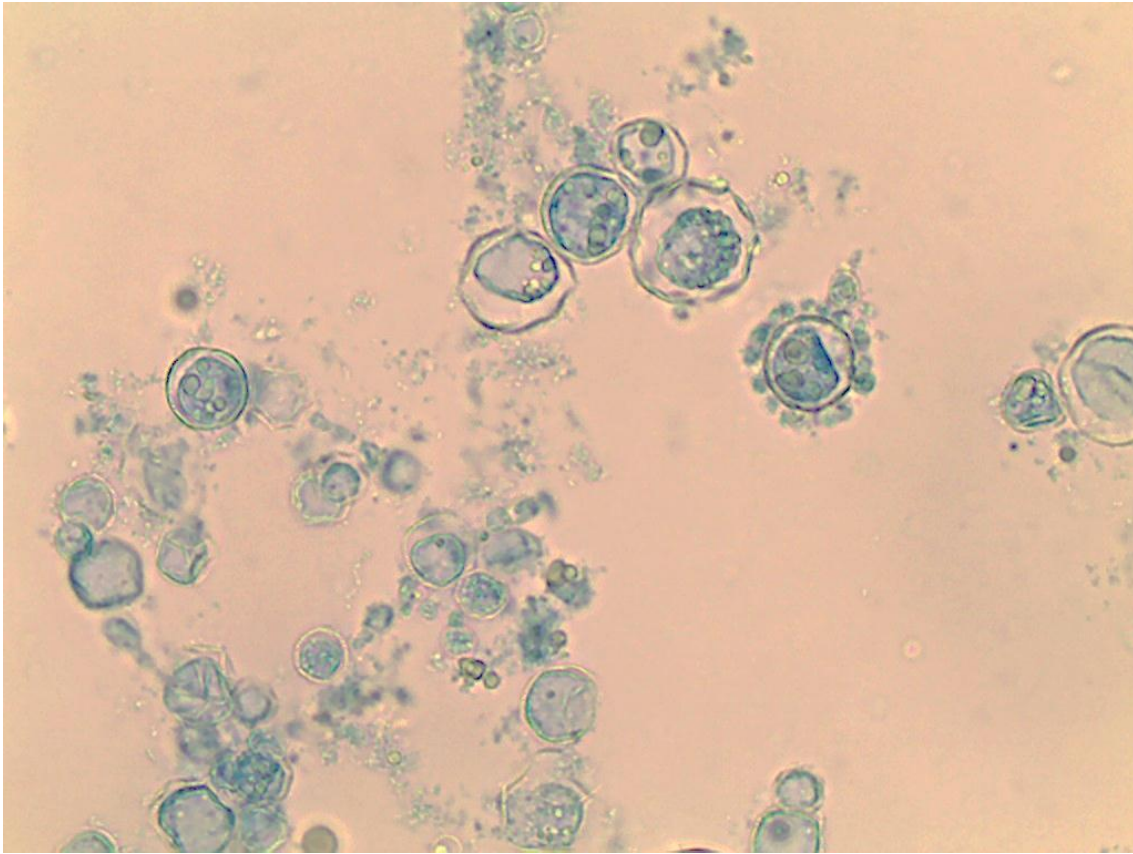
Lâmina 51: Exame direto de raspado cutâneo, 400x.



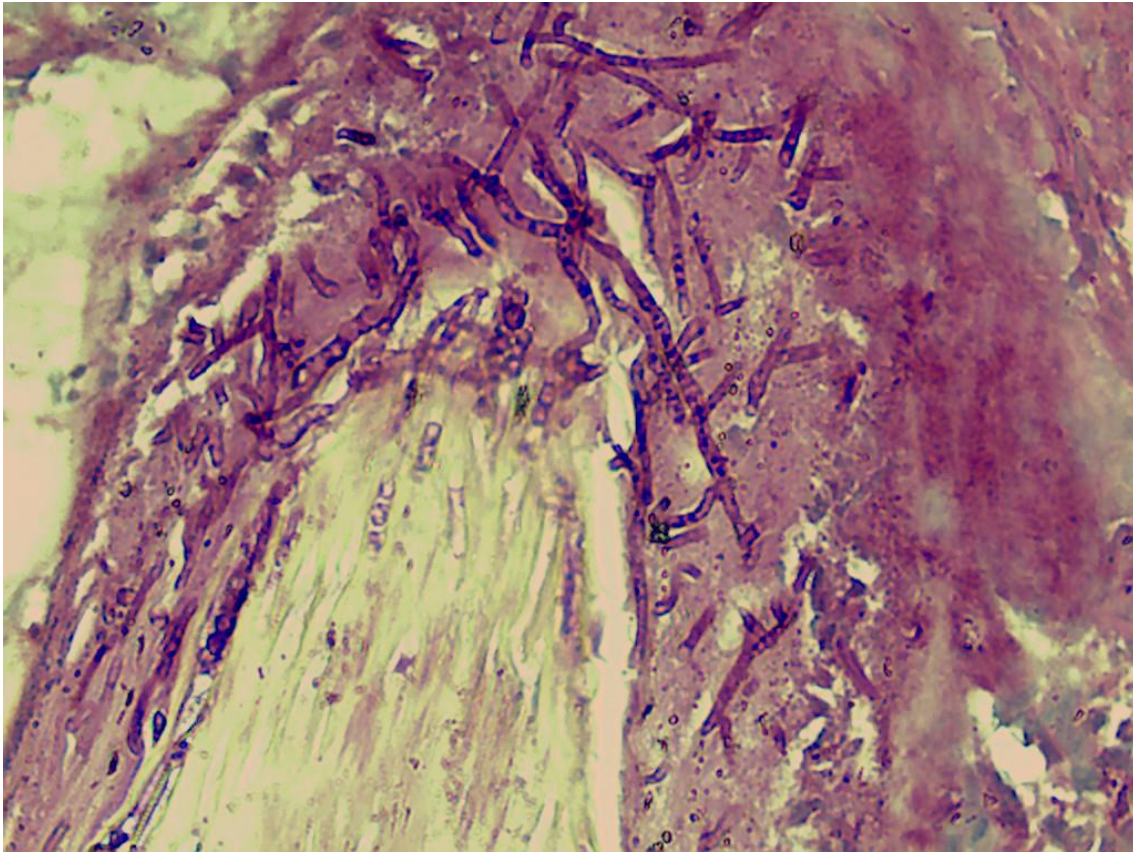
Lâmina 52: Exame direto de secreção de face contrastado com nanquim, 400x.



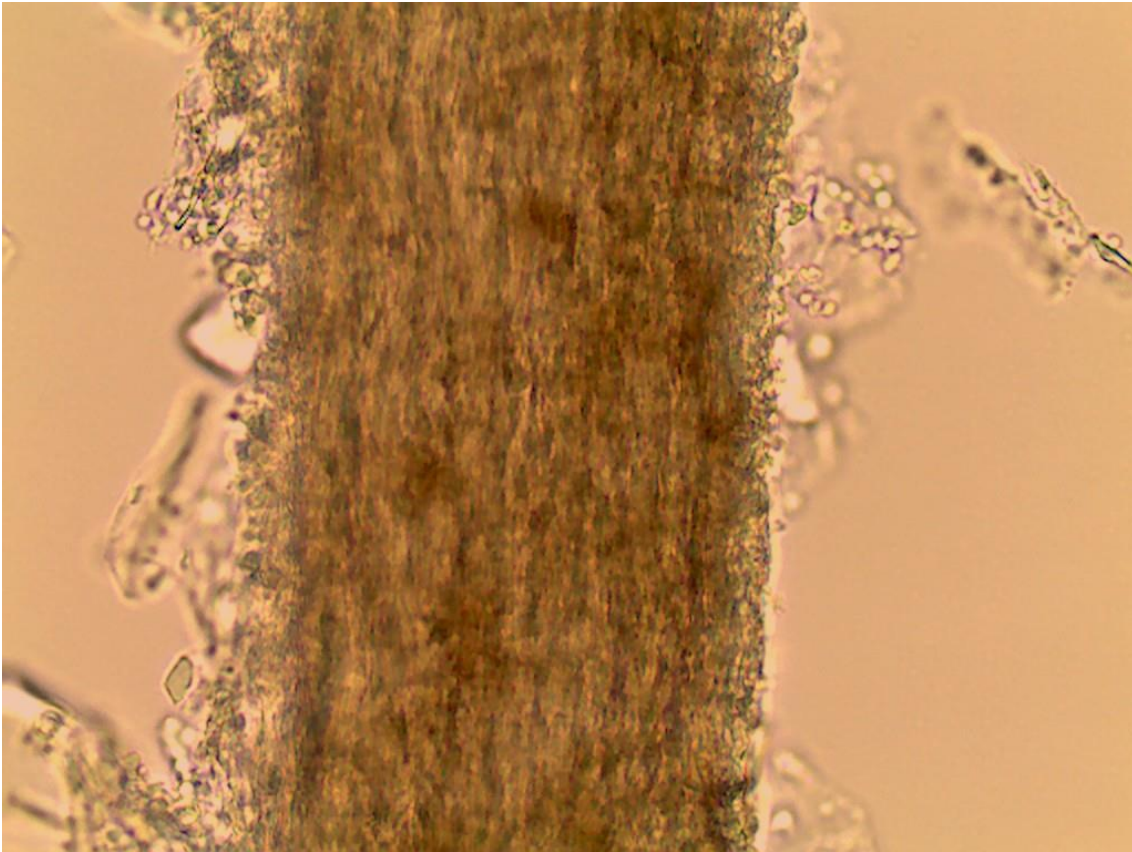
Lâmina 53: Exame direto de pus, 400x, azul algodão.



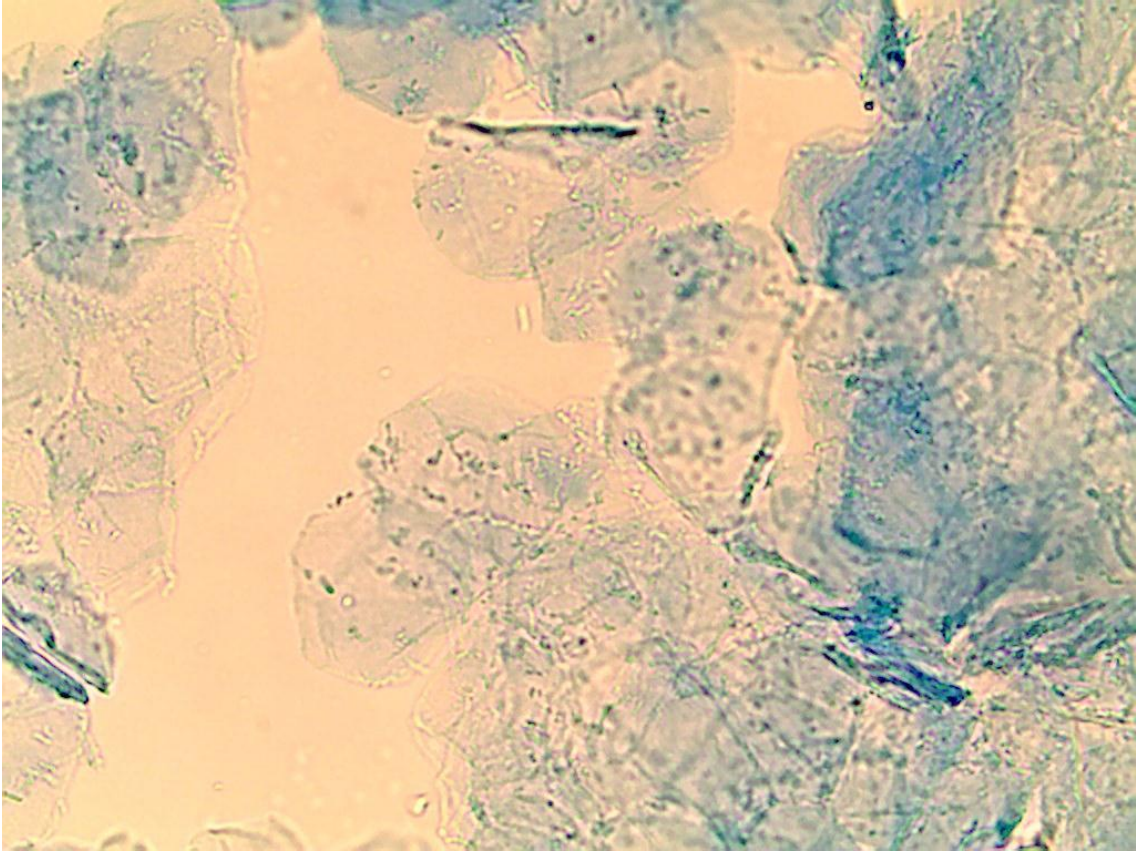
Lâmina 54: Exame histopatológico de pele corado com PAS, 400x, folículo piloso.



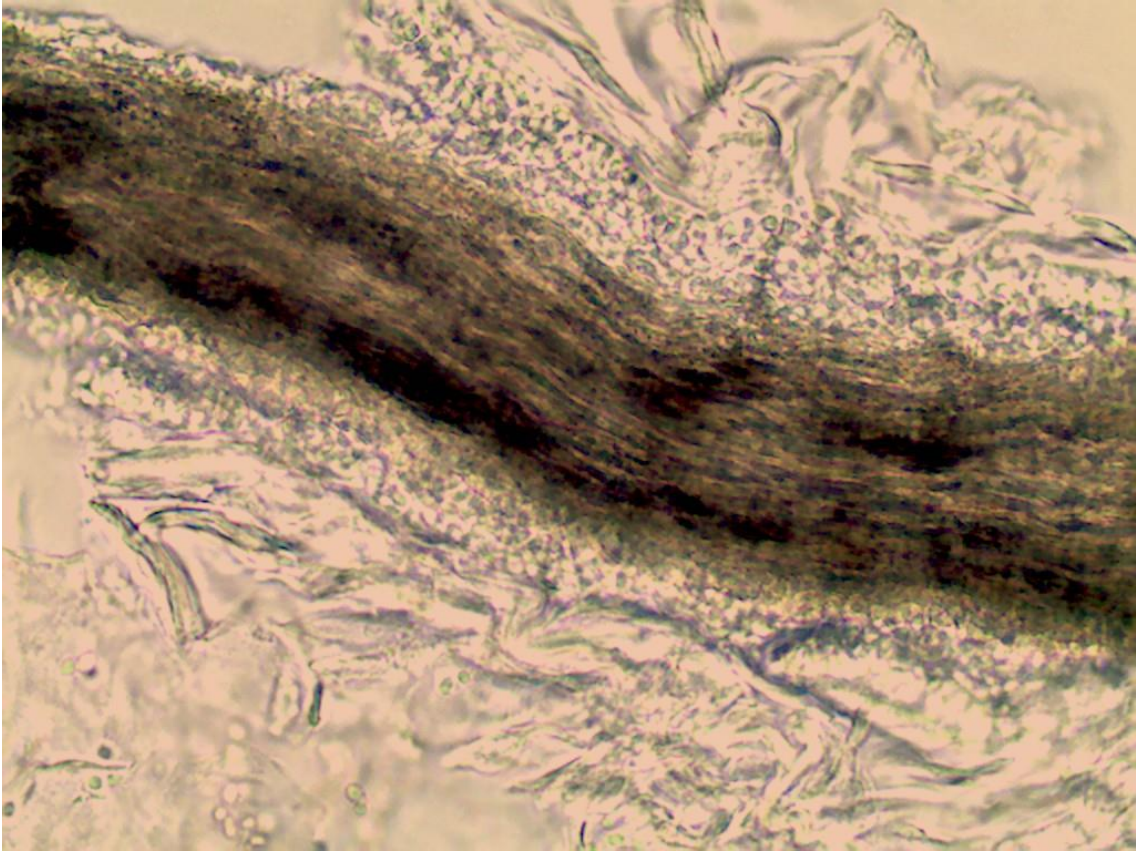
Lâmina 55: Exame direto de raspado couro cabeludo, 400x.



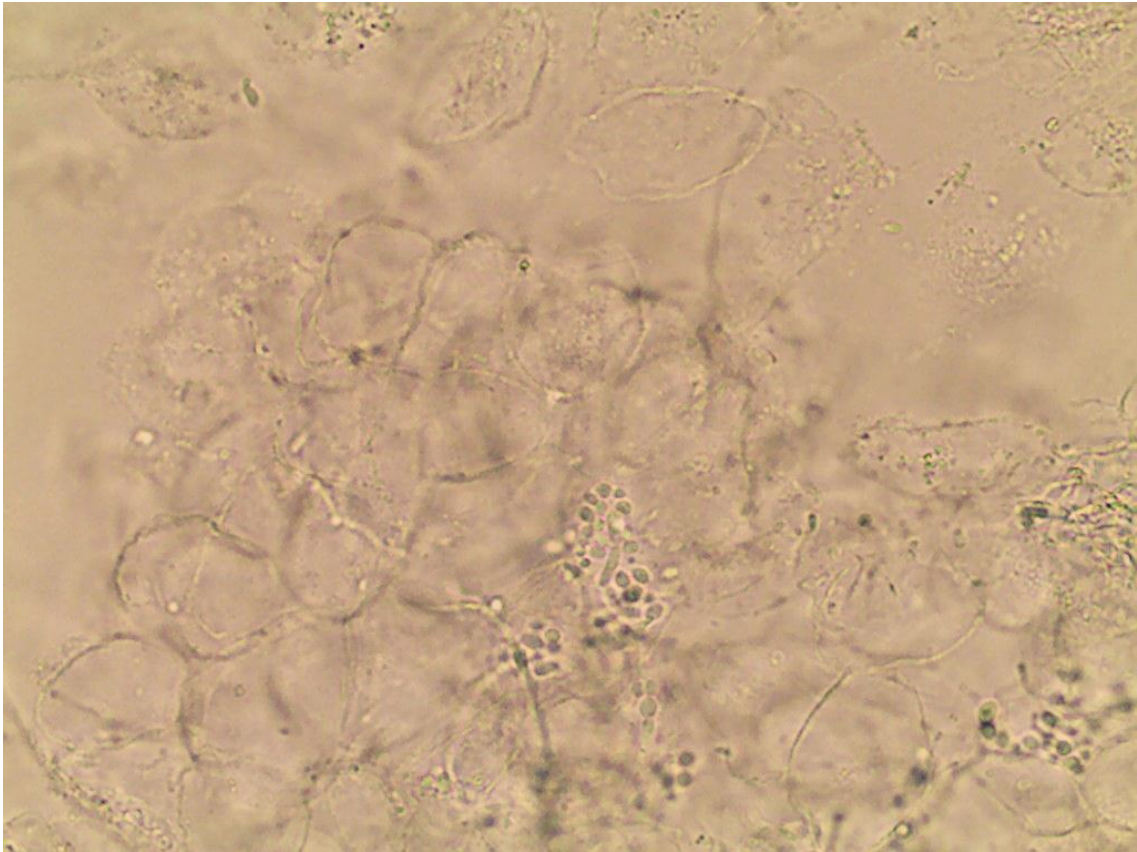
Lâmina 56: Exame direto de lesão cutânea com azul algodão, 400x.



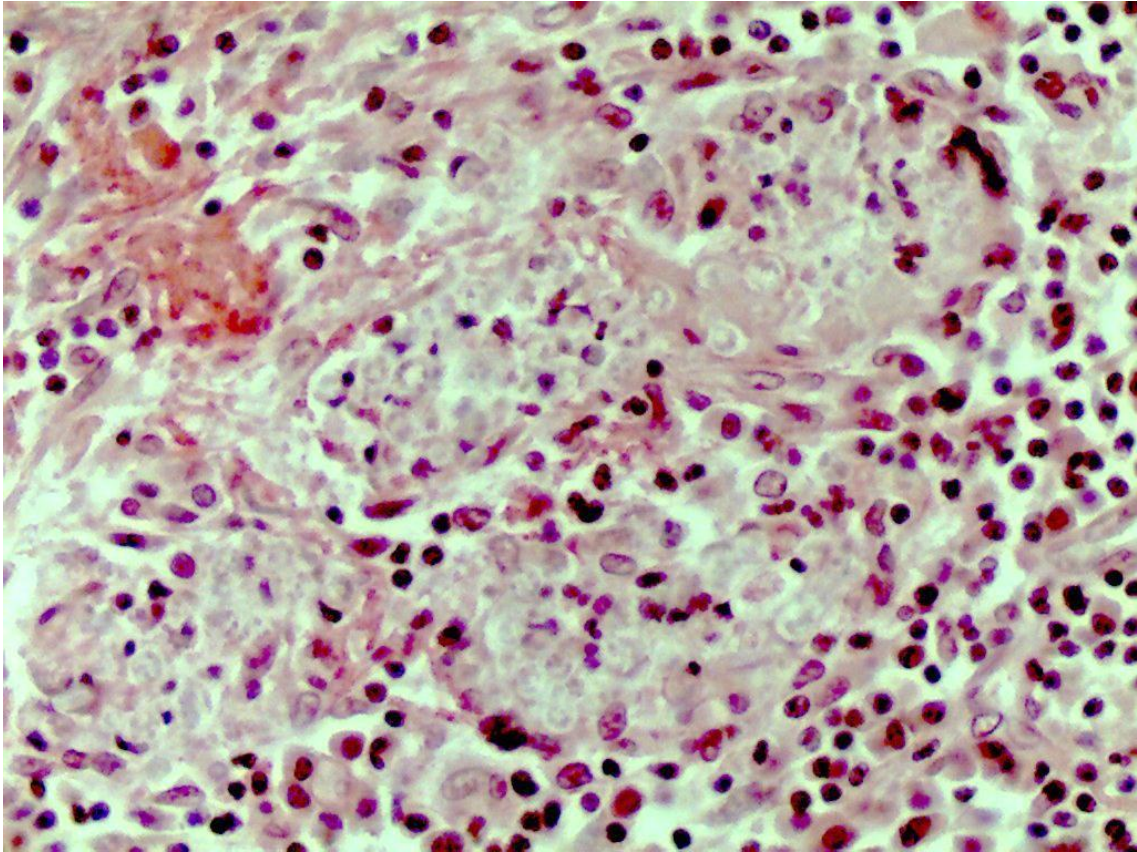
Lâmina 57: Exame direto de raspado couro cabeludo, 400x.



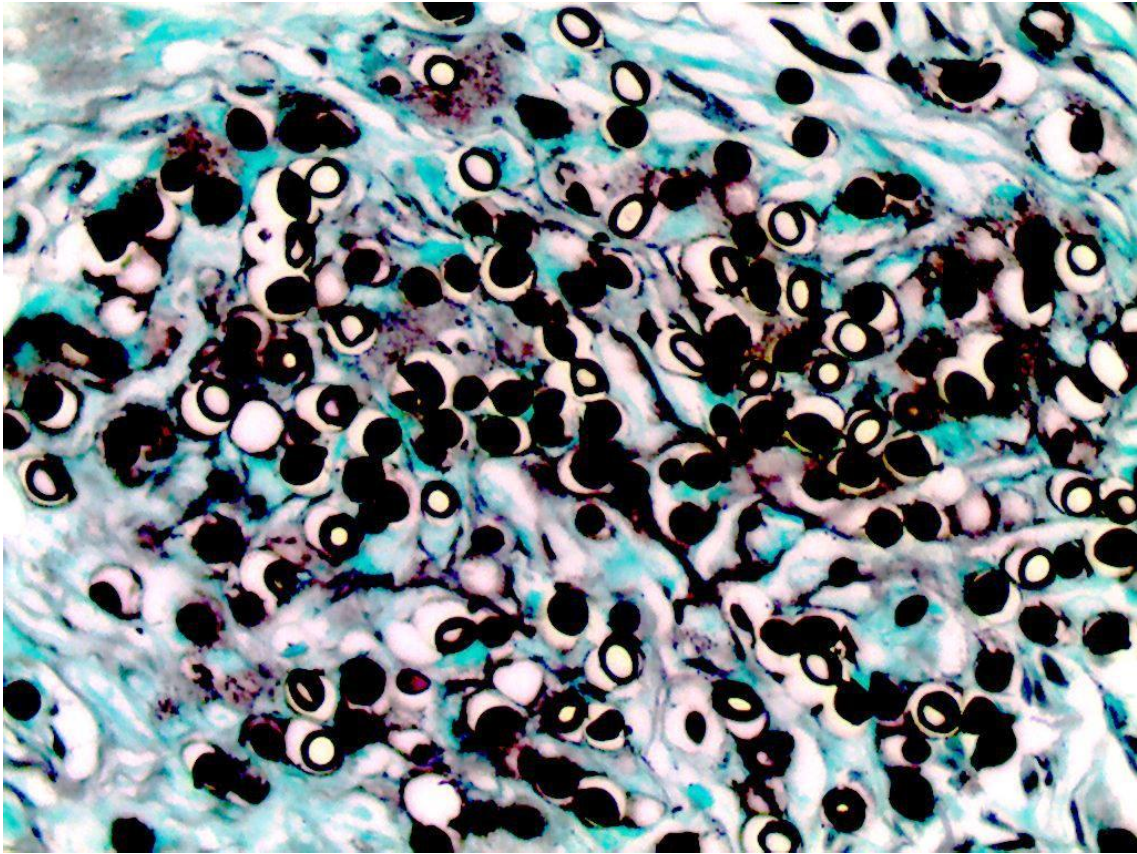
Lâmina 58: Exame direto de biópsia nódulo braço esquerdo, 400x.



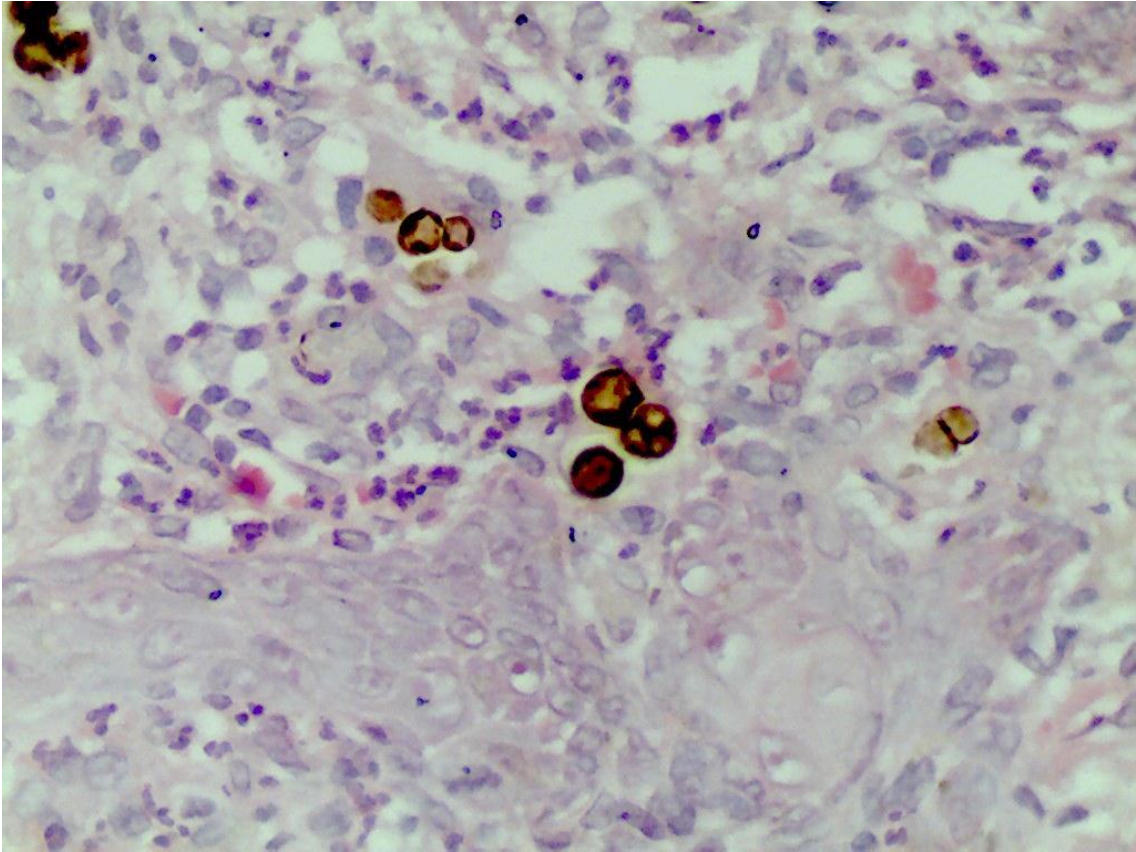
Lâmina 59: Exame histopatológico de lesão granulomatosa do nariz de paciente de região rural, HE, 400x



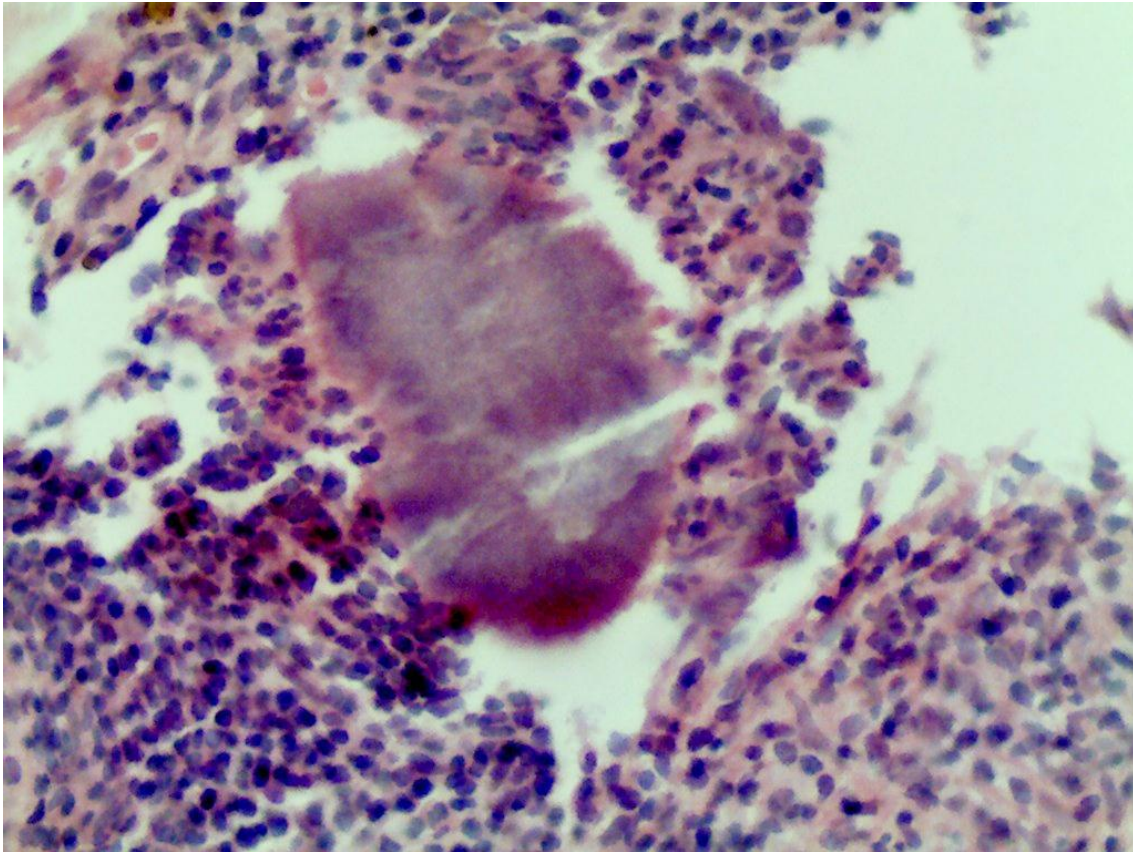
Lâmina 60: Exame histopatológico de lesão nodular na orelha de paciente de São Luiz, Maranhão, Grocott, 400x.



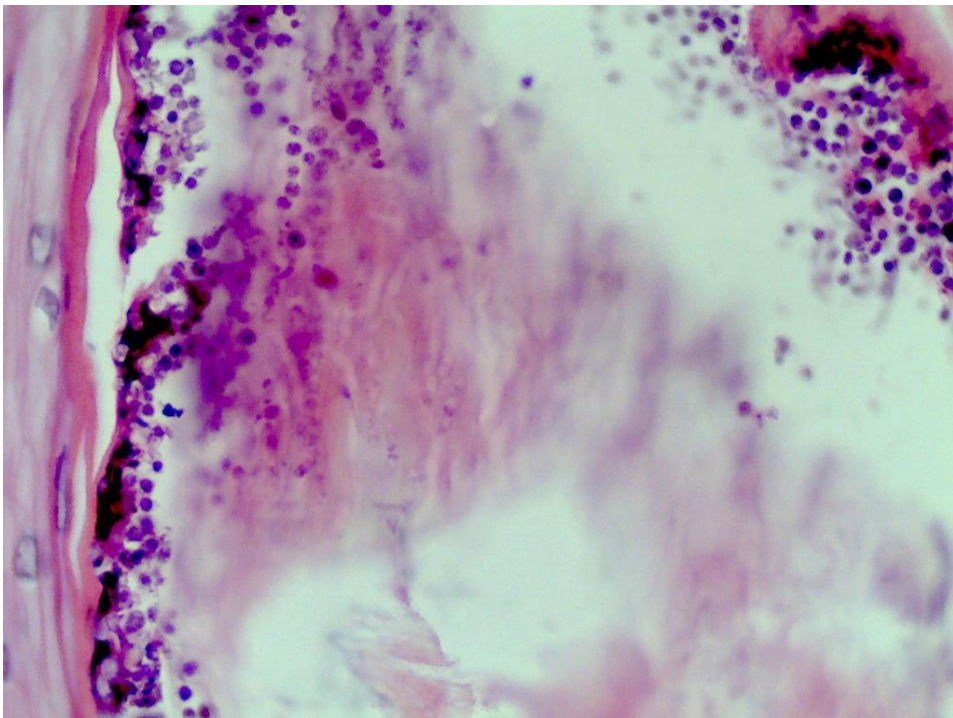
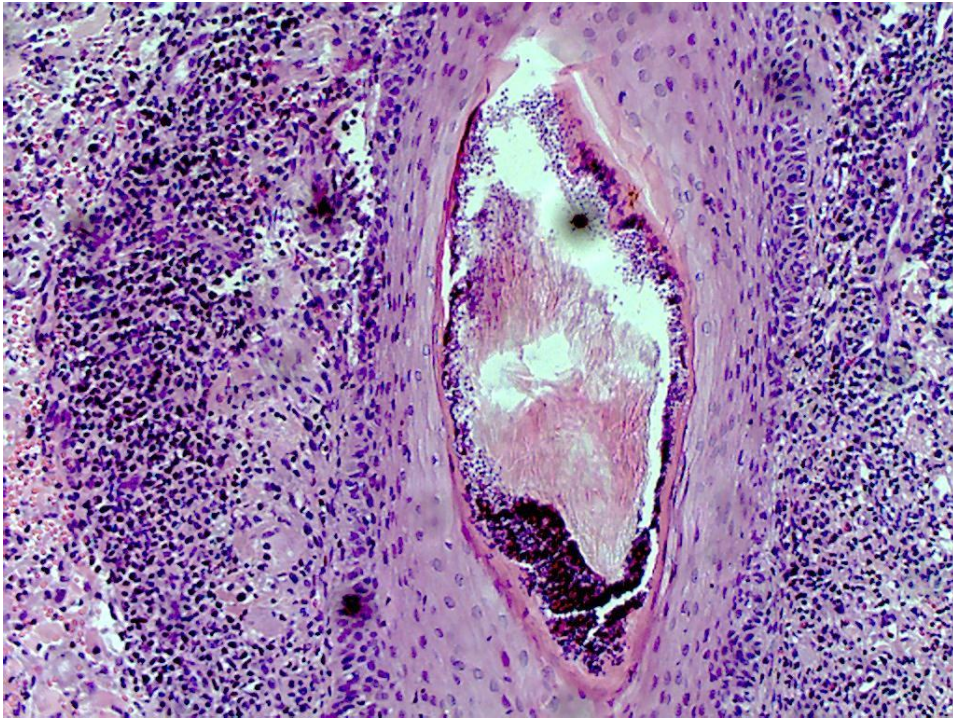
Lâmina 61: Exame histopatológico de lesão verrucóide no pé direito, HE, 400x.



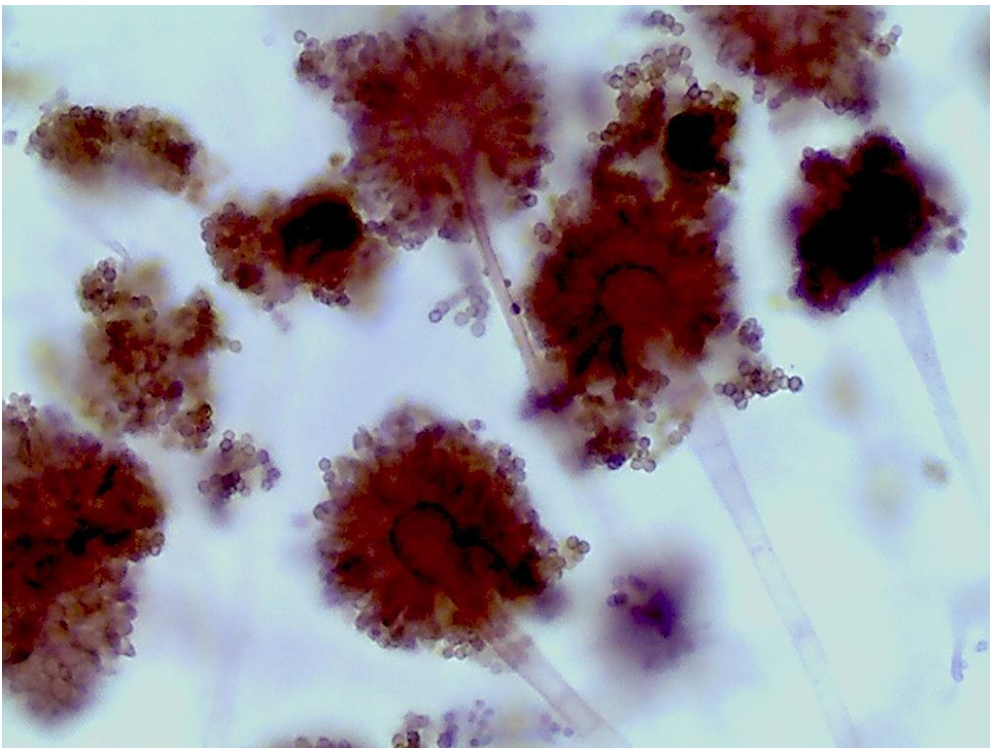
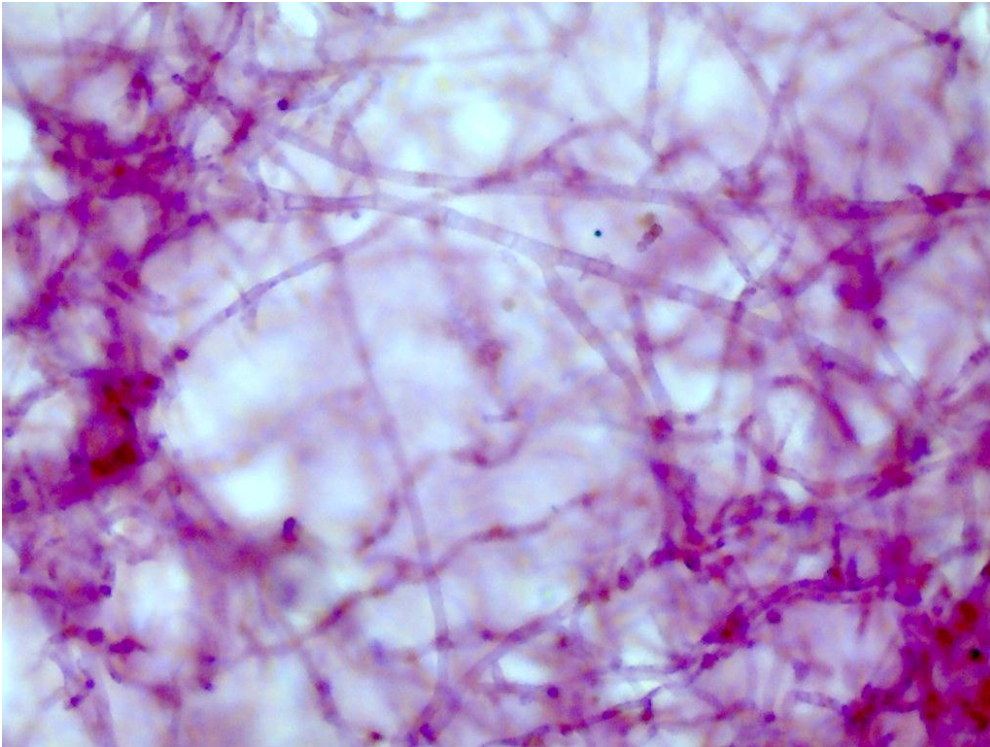
Lâmina 62: Exame histopatológico de tumor no braço de 10 anos de evolução, HE, 400x.



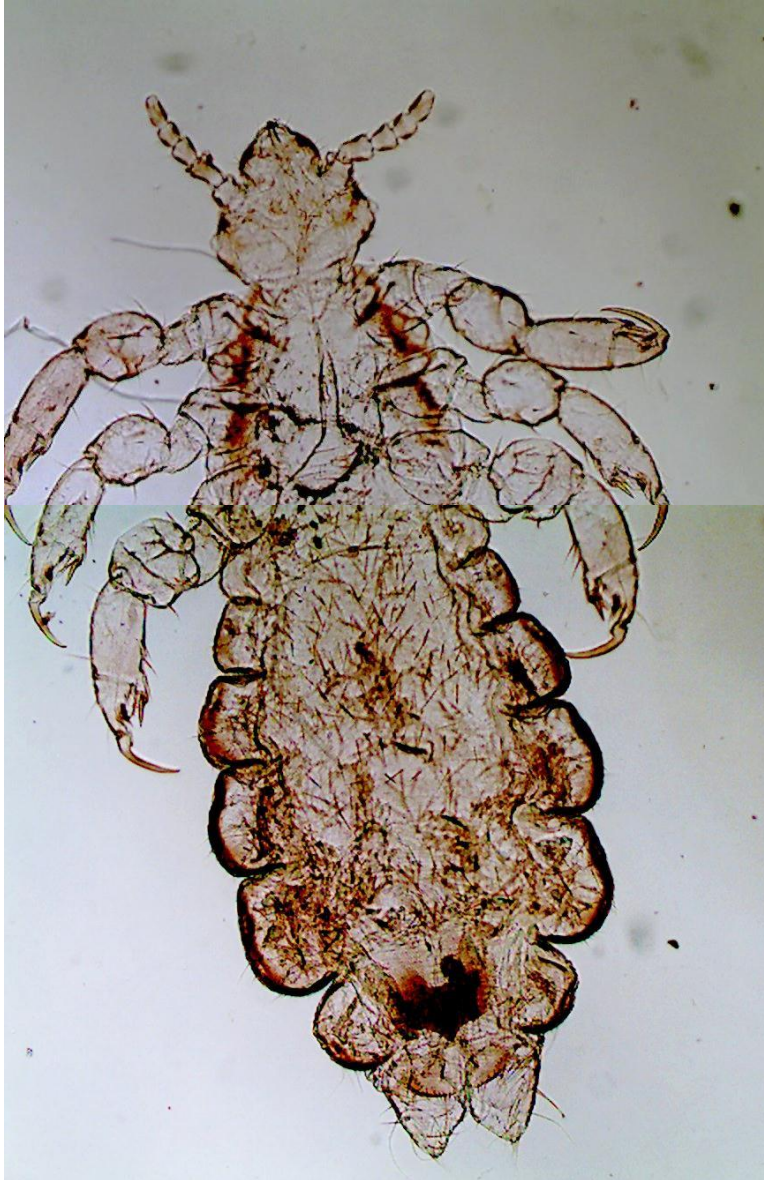
Lâmina 63: Exame histopatológico de biópsia de foliculite da barba, HE, 100x e 400x respectivamente.



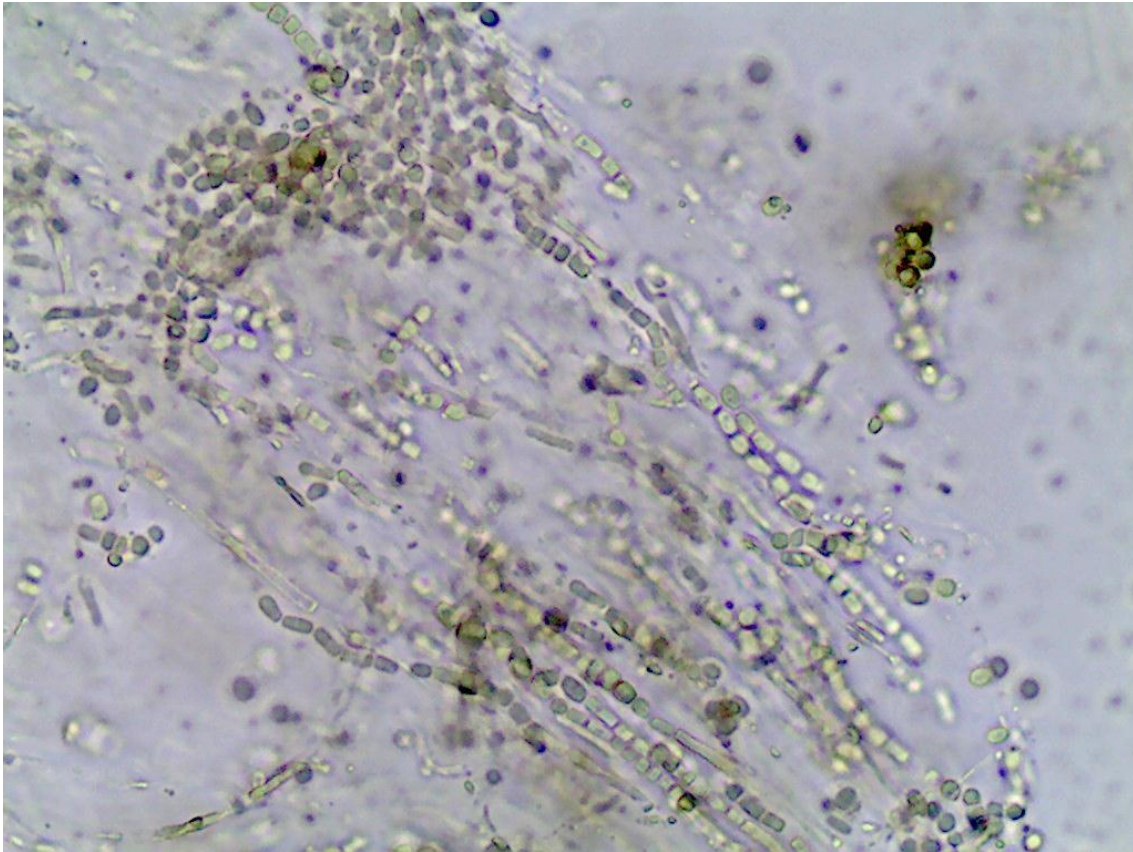
Lâmina 64: Exame direto de massa tumoral no seio malar, PAS, 400x.



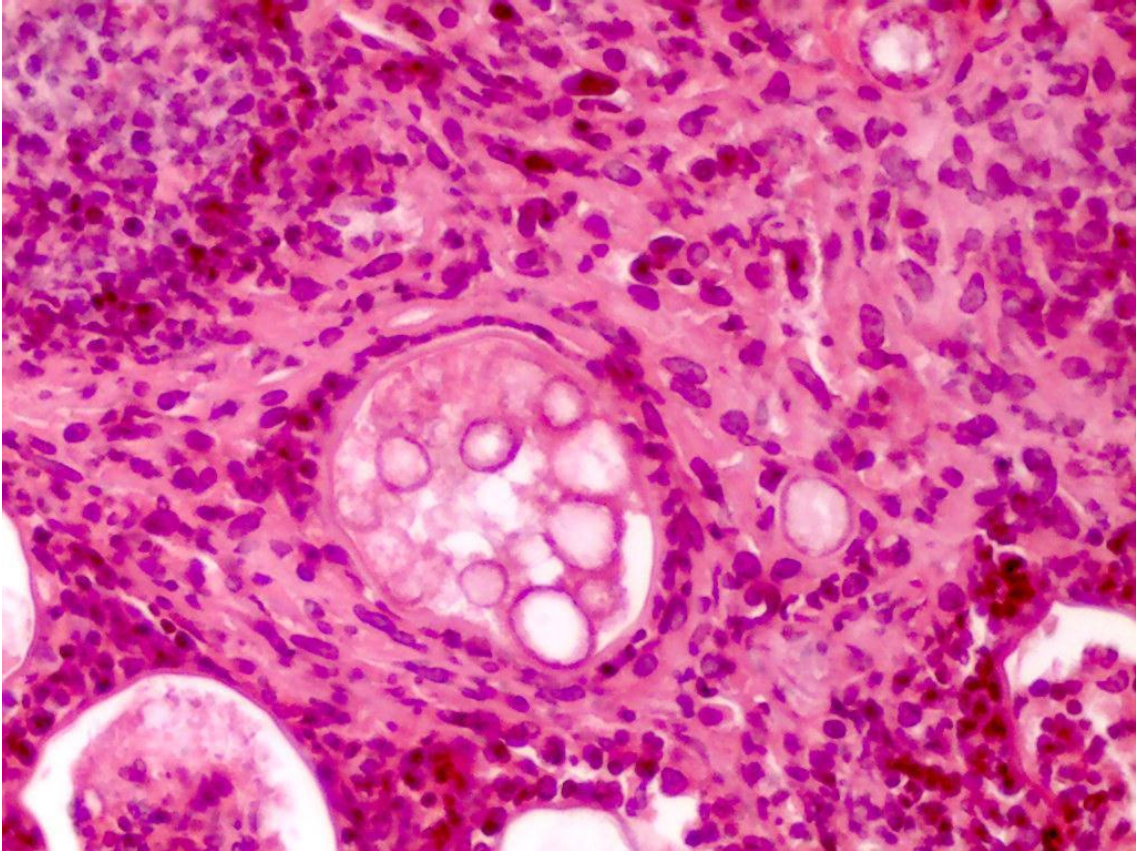
Lâmina 65: Exame direto de nódulos no cabelo de criança 5 anos, 40x.



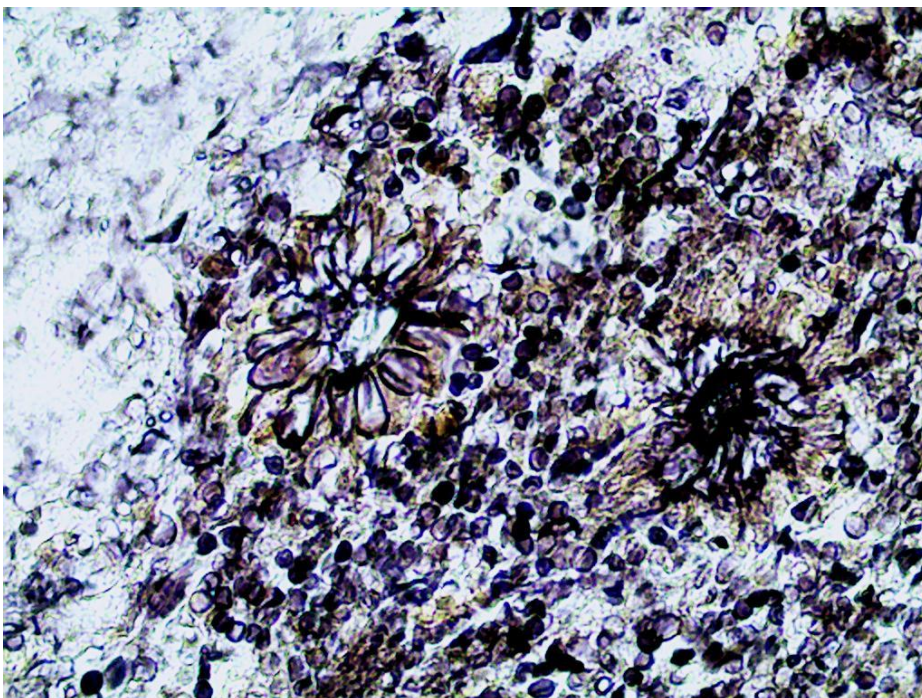
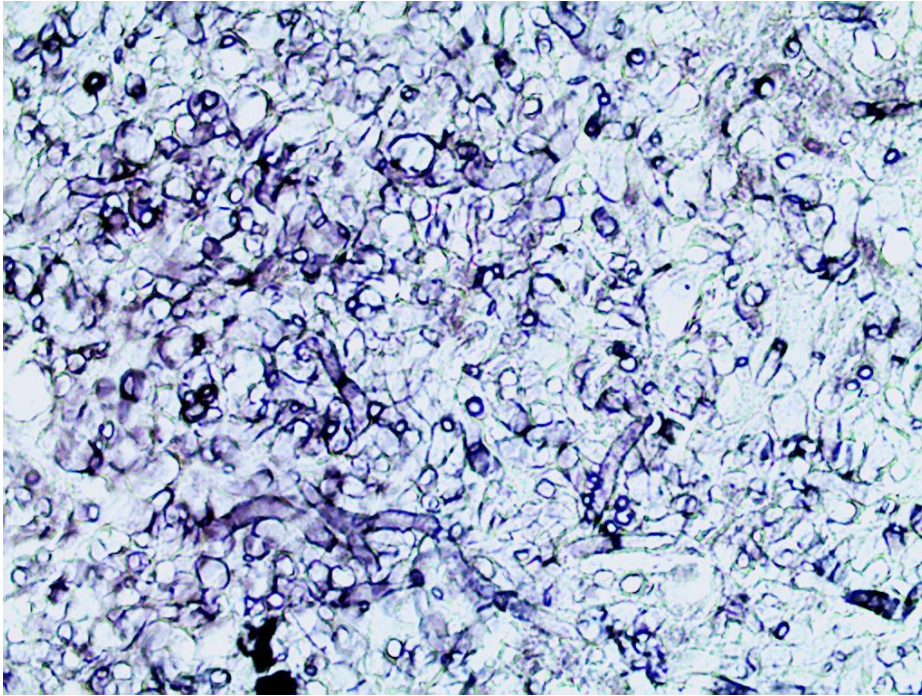
Lâmina 66: Micromorfologia de colônia de fungo, 400x.



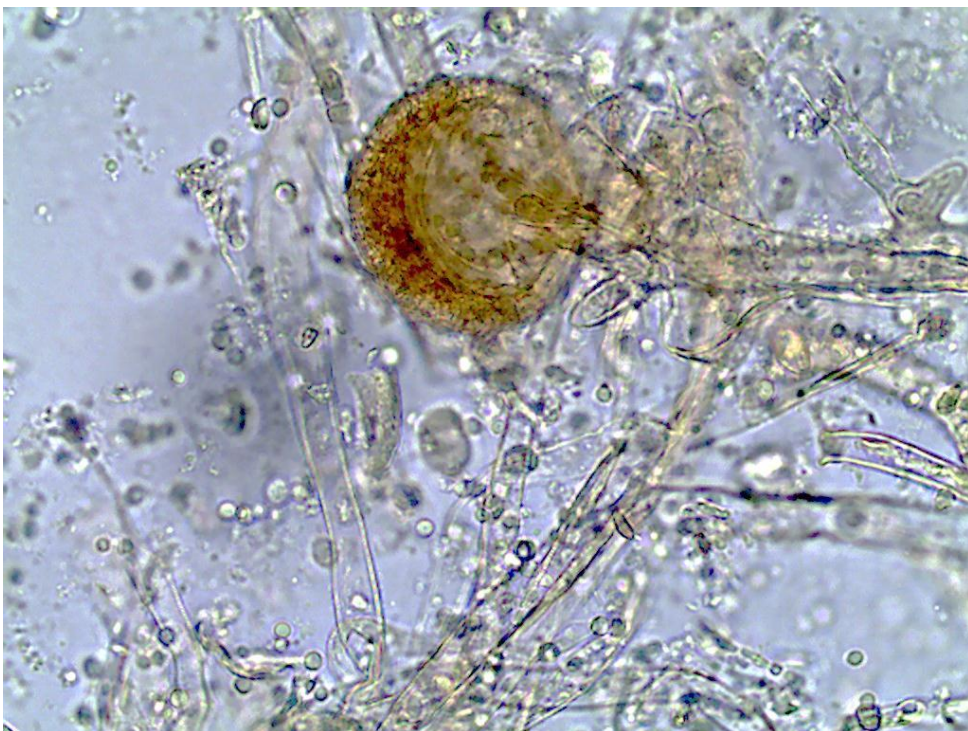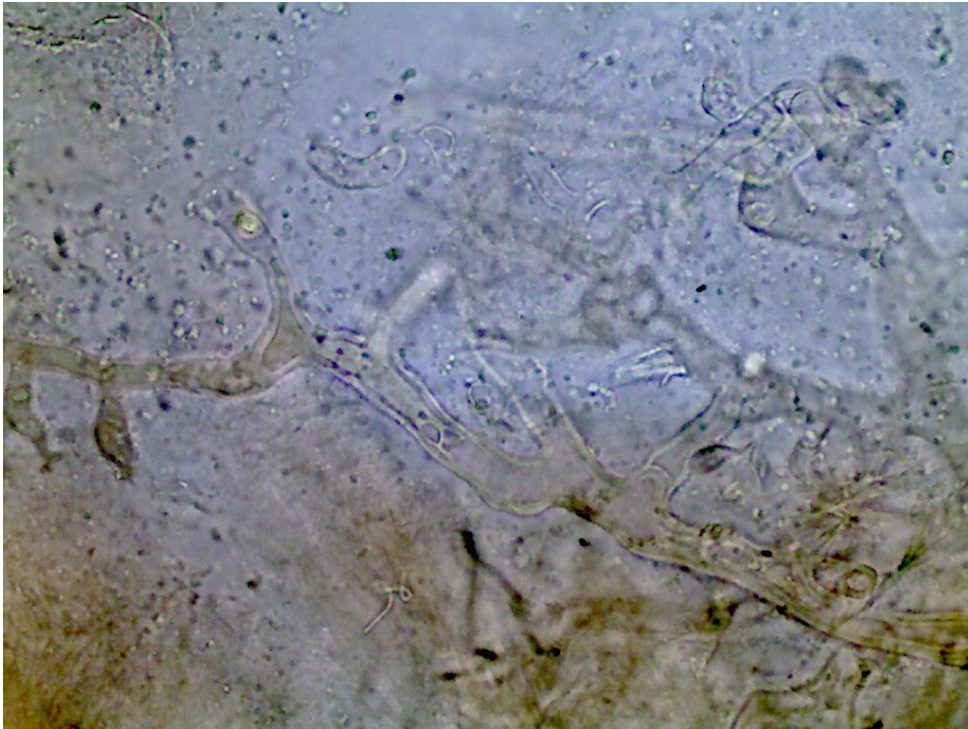
Lâmina 67: Exame histopatológico de nódulo abscedado no pescoço, HE, 400x.



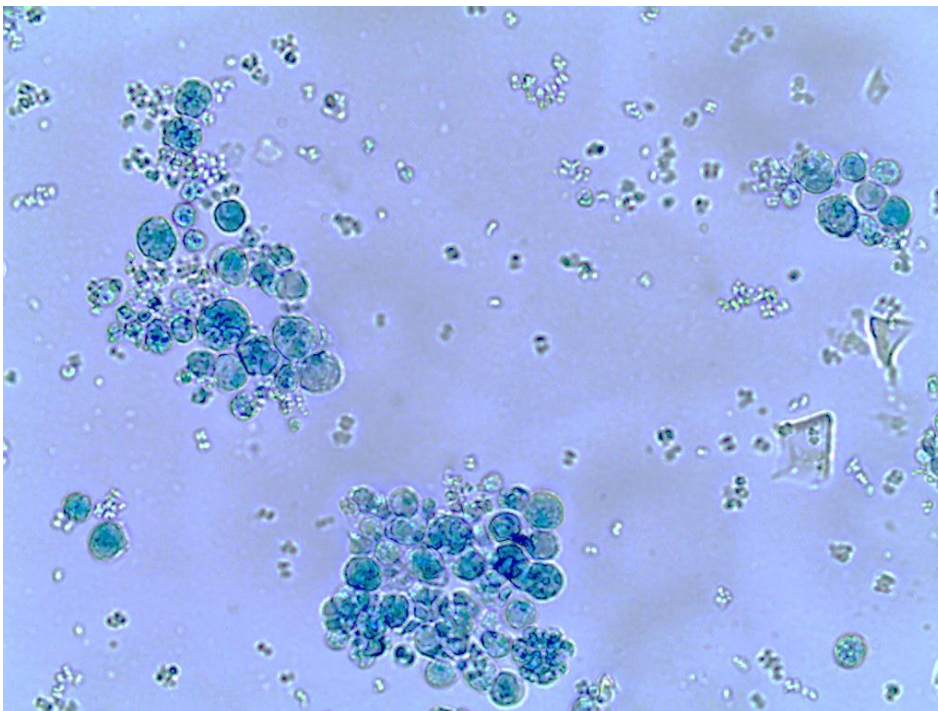
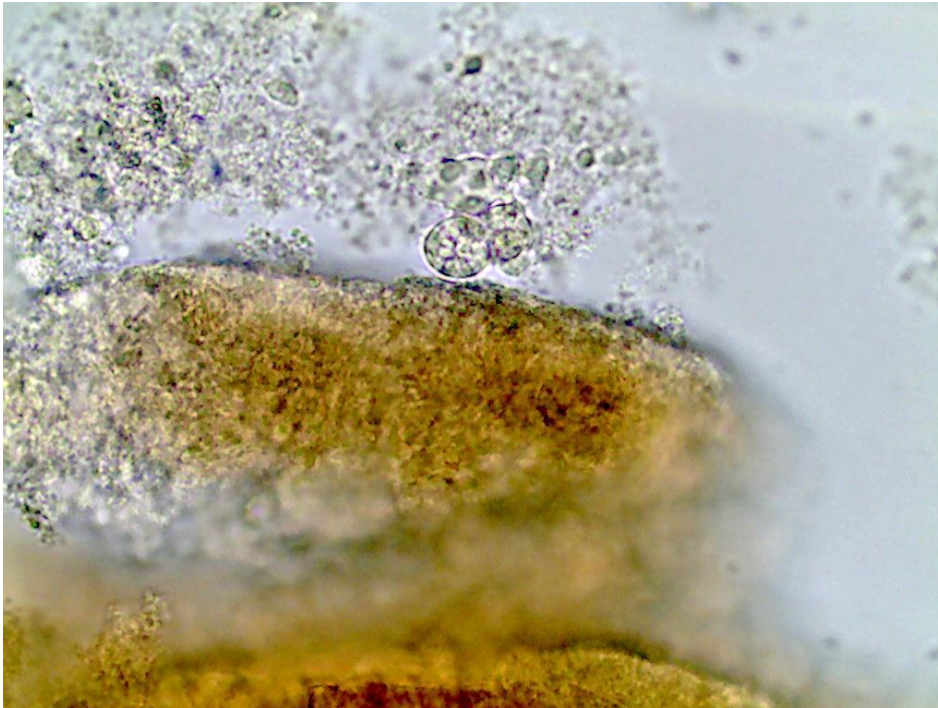
Lâmina 68: Exame histopatológico de lesão de face disseminada de seio frontal, Grocott, 400x.



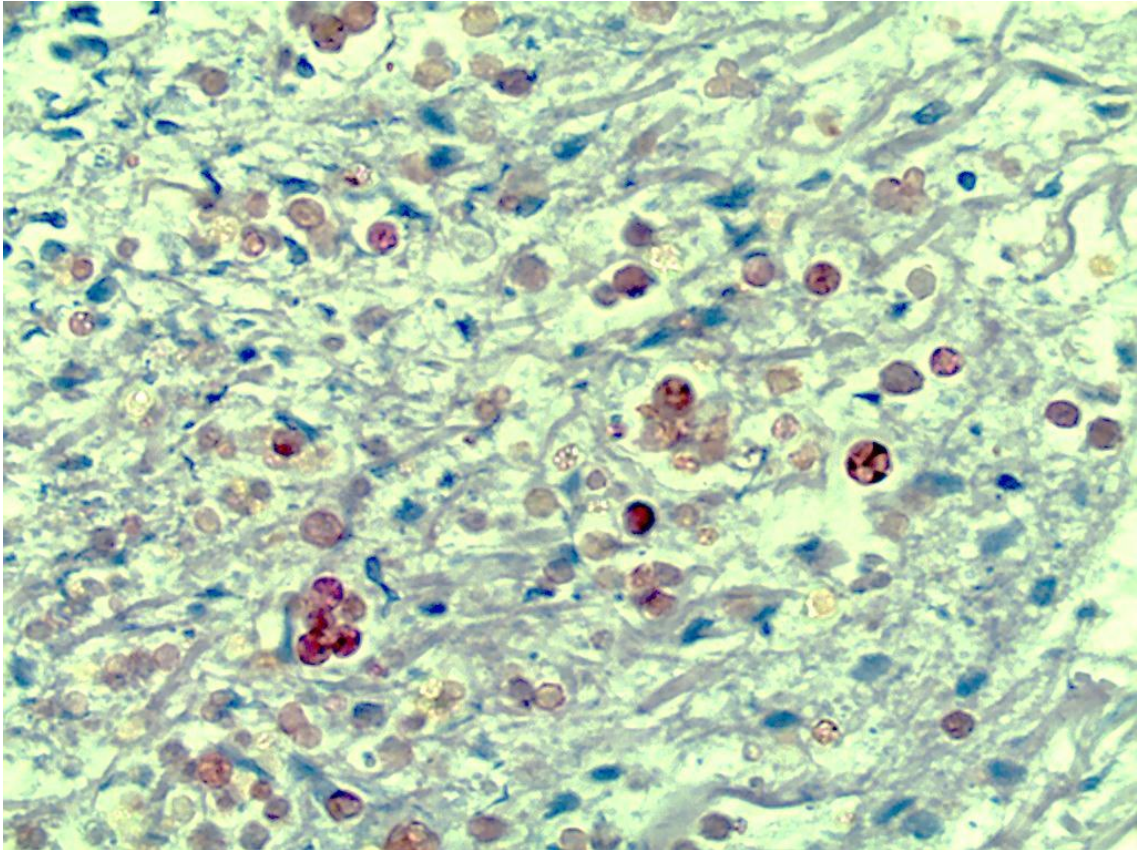
Lâmina 69: Exame direto de lesão necrótica de face e de secreção do nariz em paciente diabético, 400x.



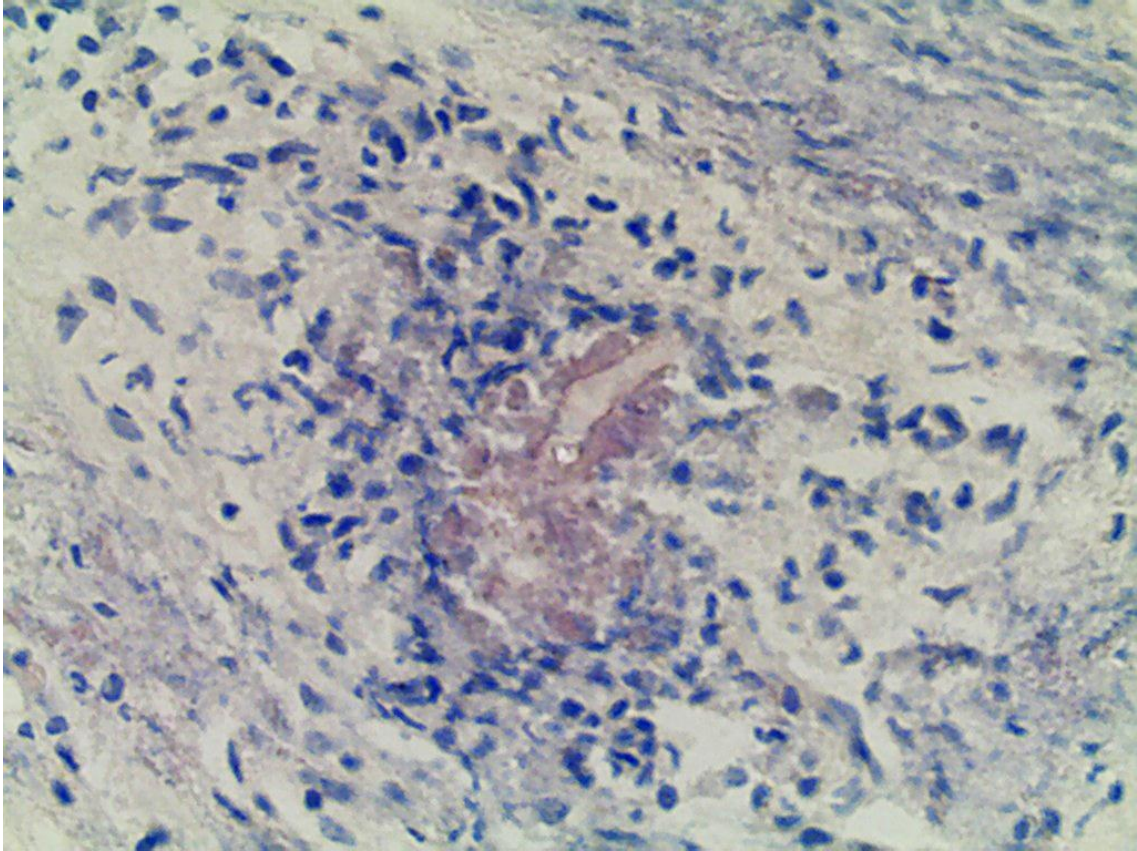
Lâmina 70: Exame direto de biópsia de lesão ulcerada no braço e micromorfologia de colônia respectivamente, 400x.



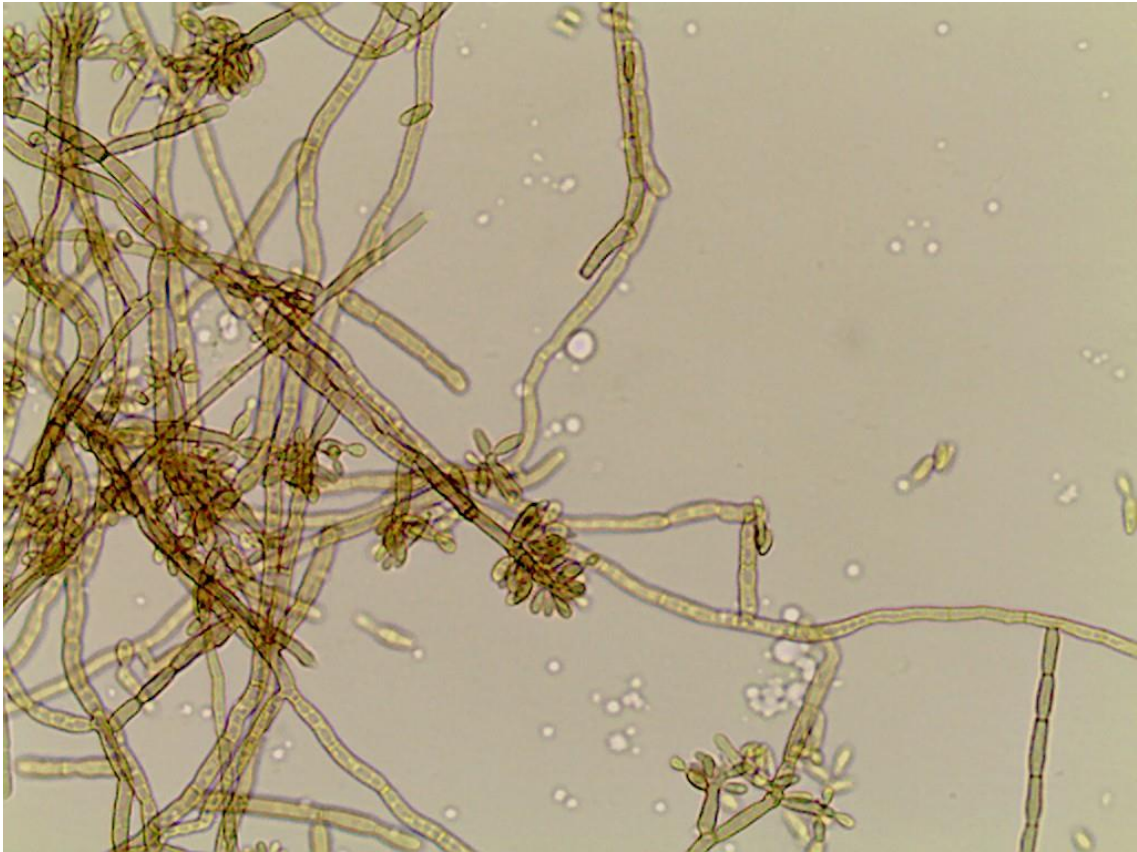
Lâmina 71: Exame histopatológico do caso anterior (Lâmina 70), PAS, 400x.



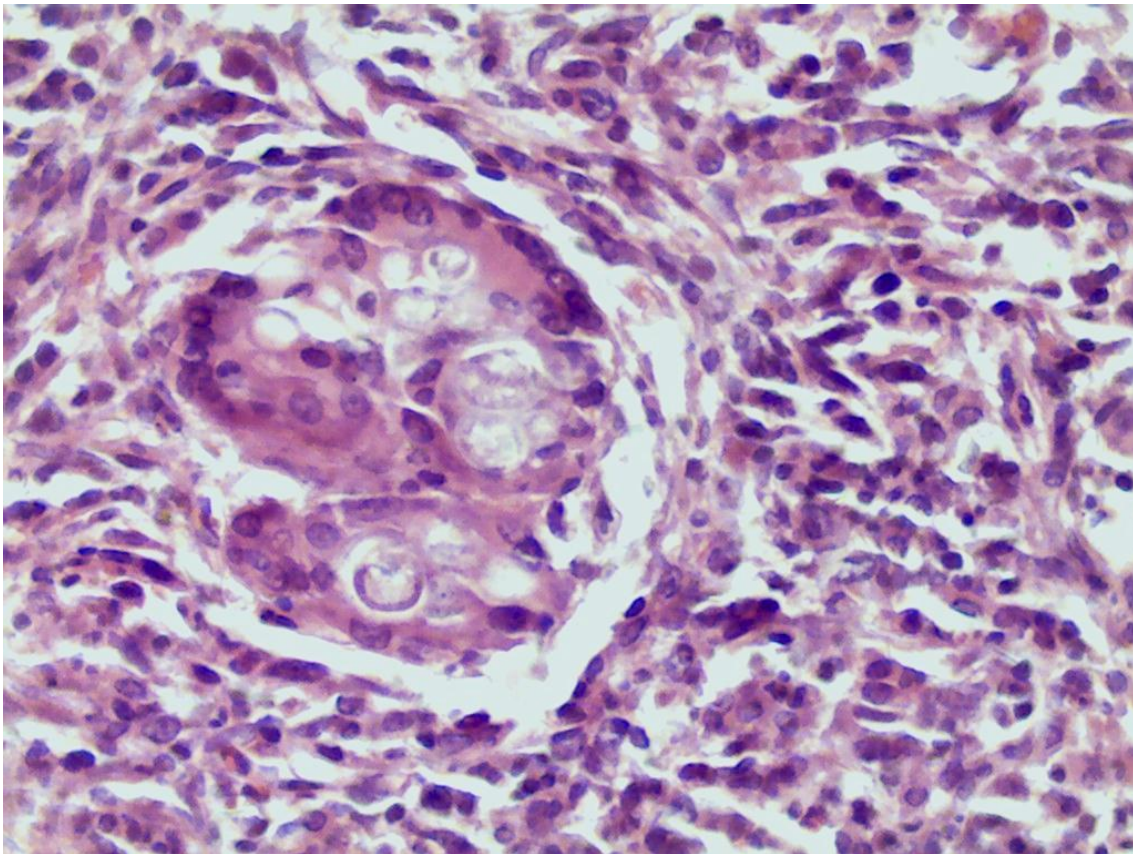
Lâmina 72: Exame histopatológico de lesão tumoral de face, PAS, 400x.



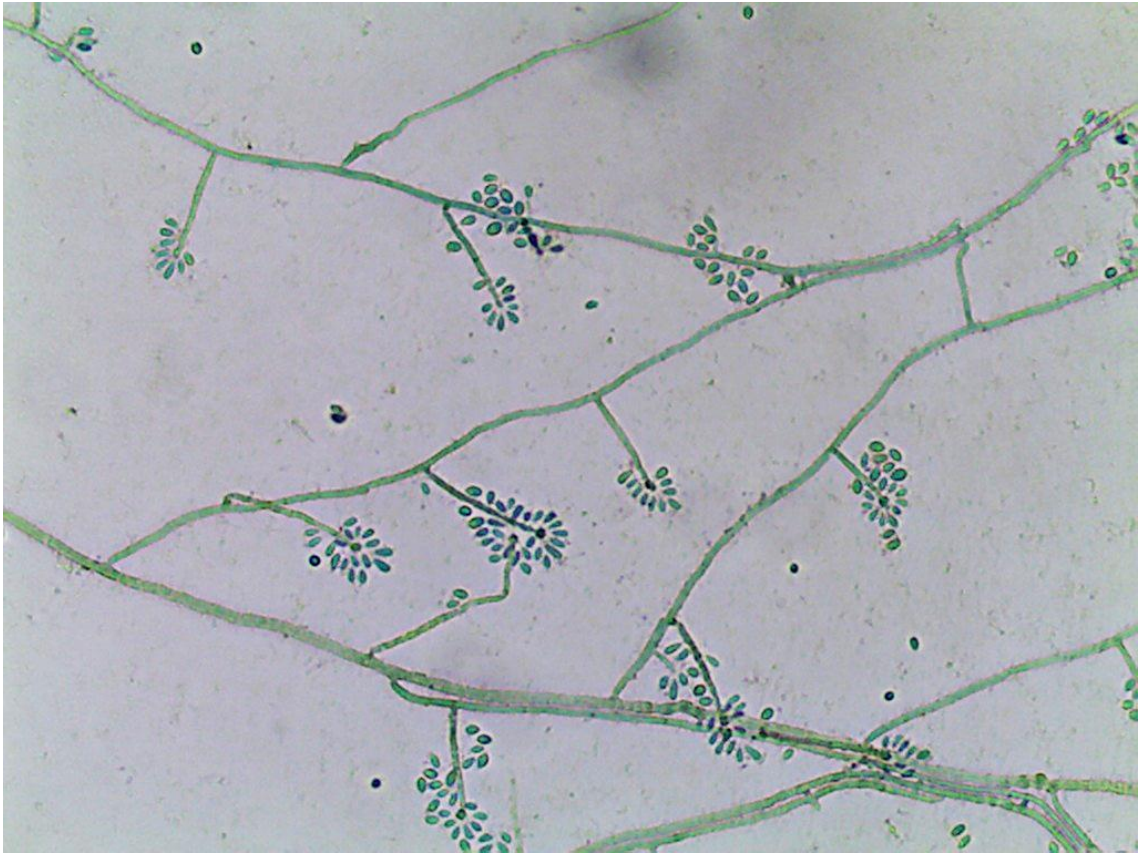
Lâmina 73: Micromorfologia de colônia, 400x.



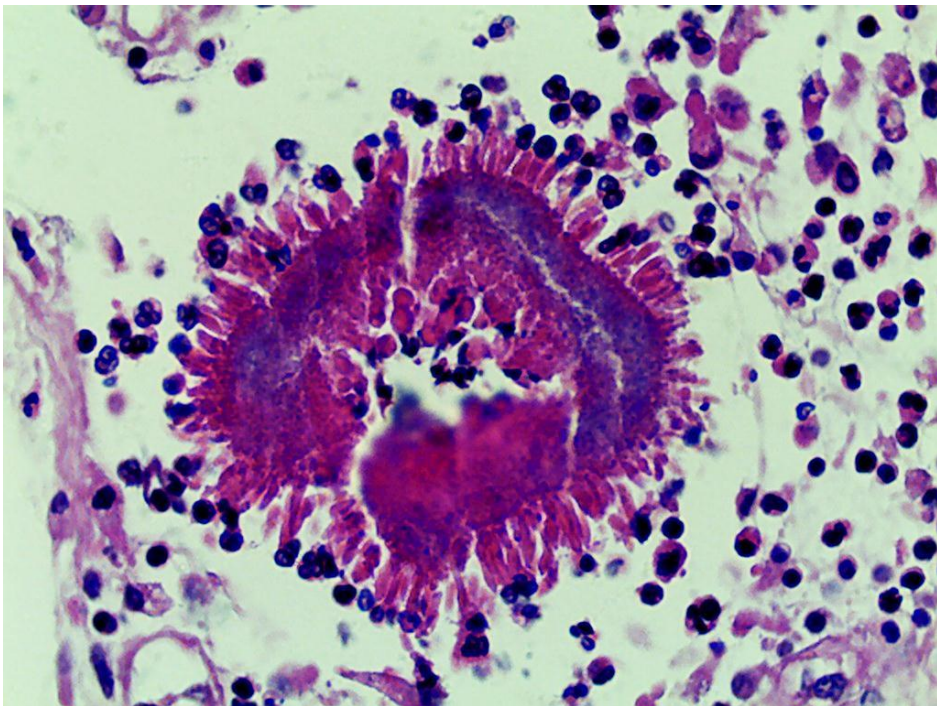
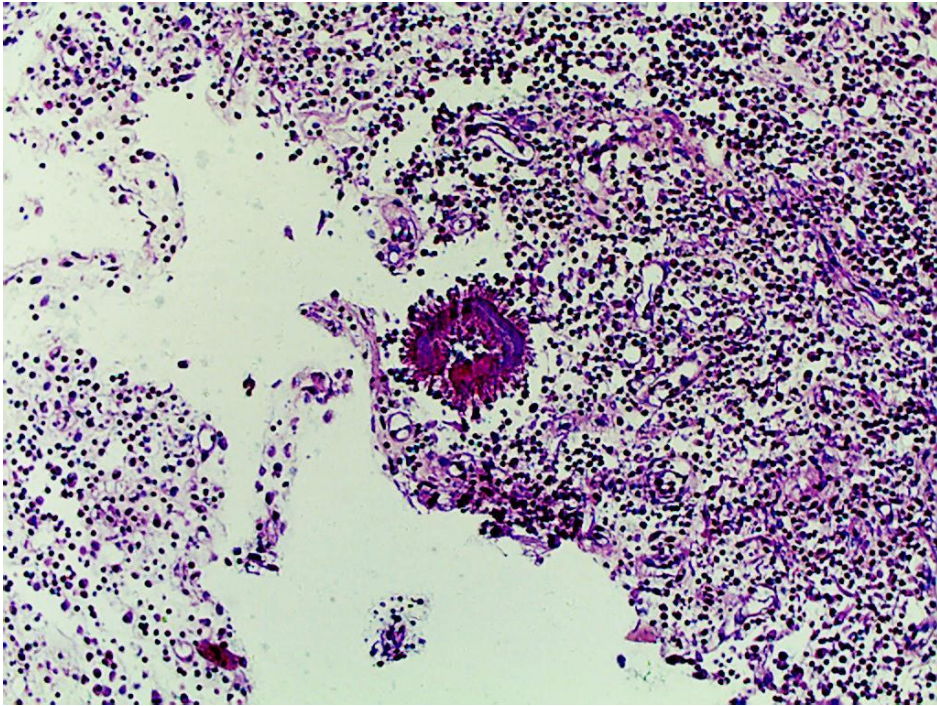
Lâmina 74: Exame histopatológico de lesão granulomatosa no braço de um americano recentemente vindo para trabalhar numa empresa multinacional, HE, 400x.



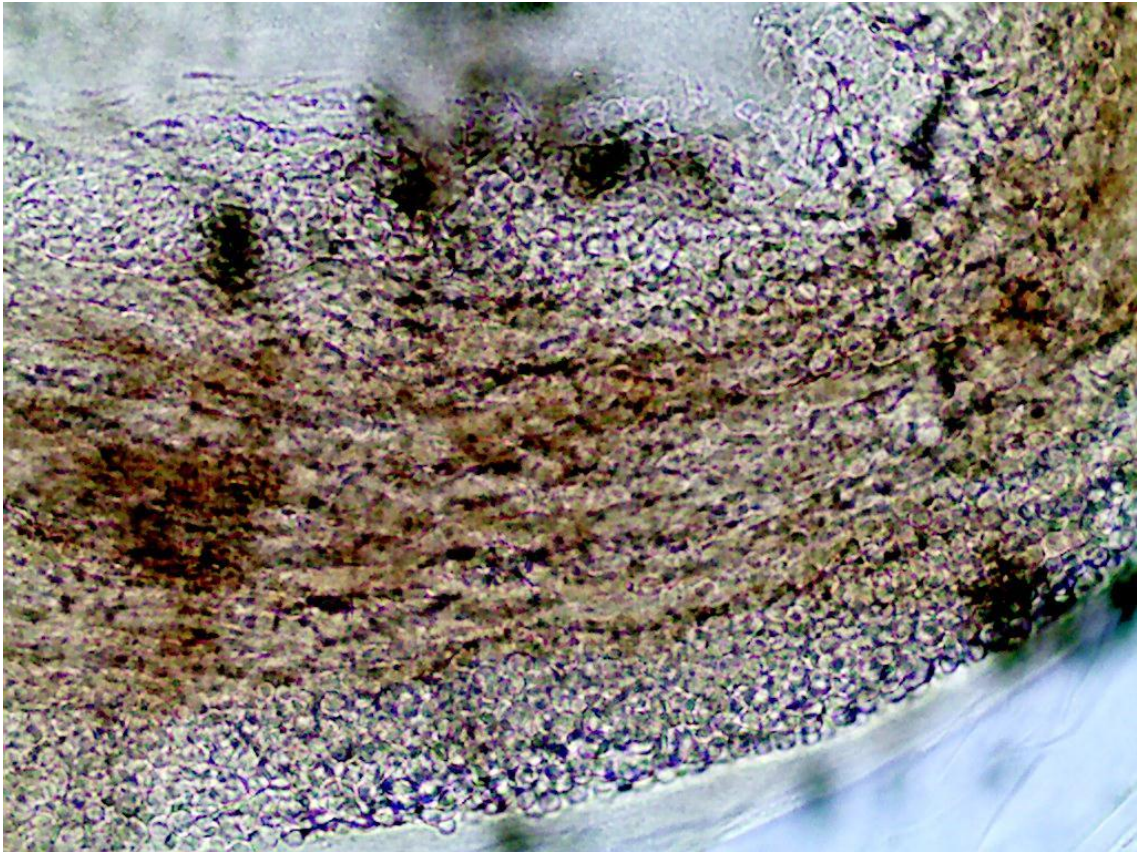
Lâmina 75: Micromorfologia de colônia, 400x.



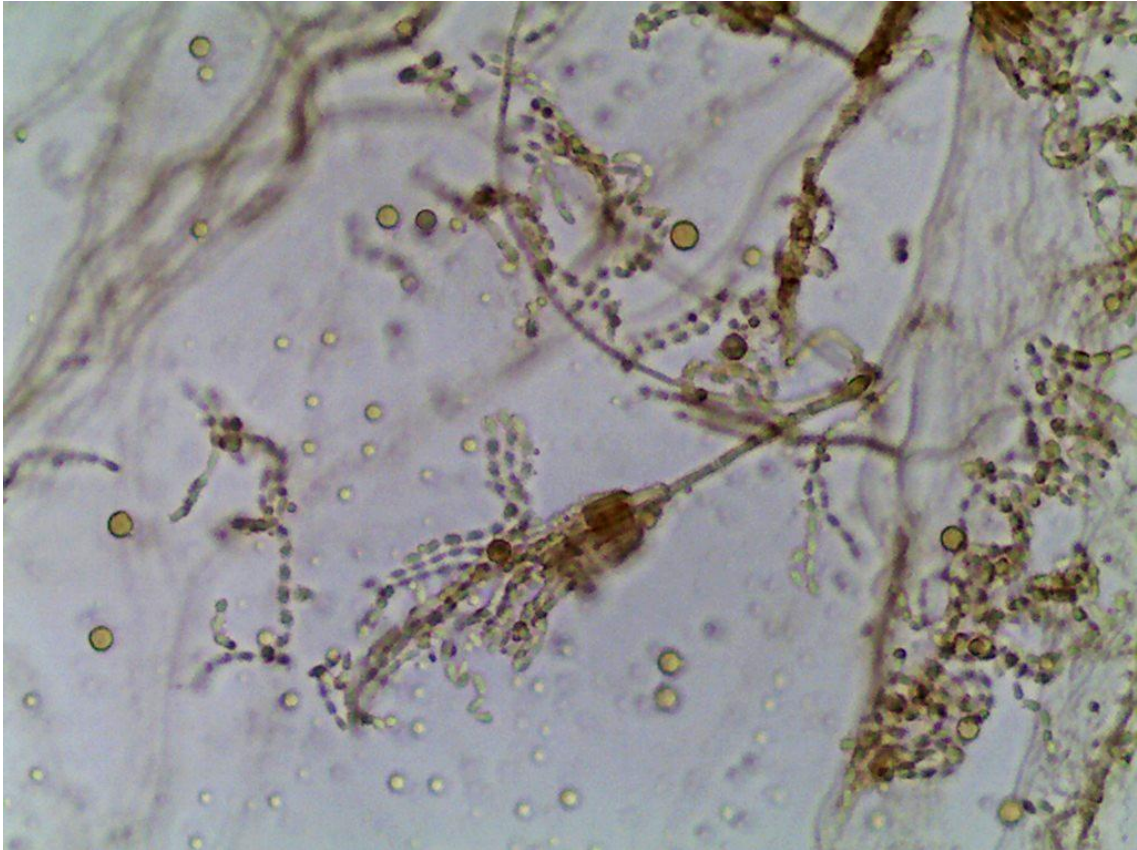
Lâmina 76: Exame histopatológico de lesão tumoral no pé, HE, 100x e 400x respectivamente.



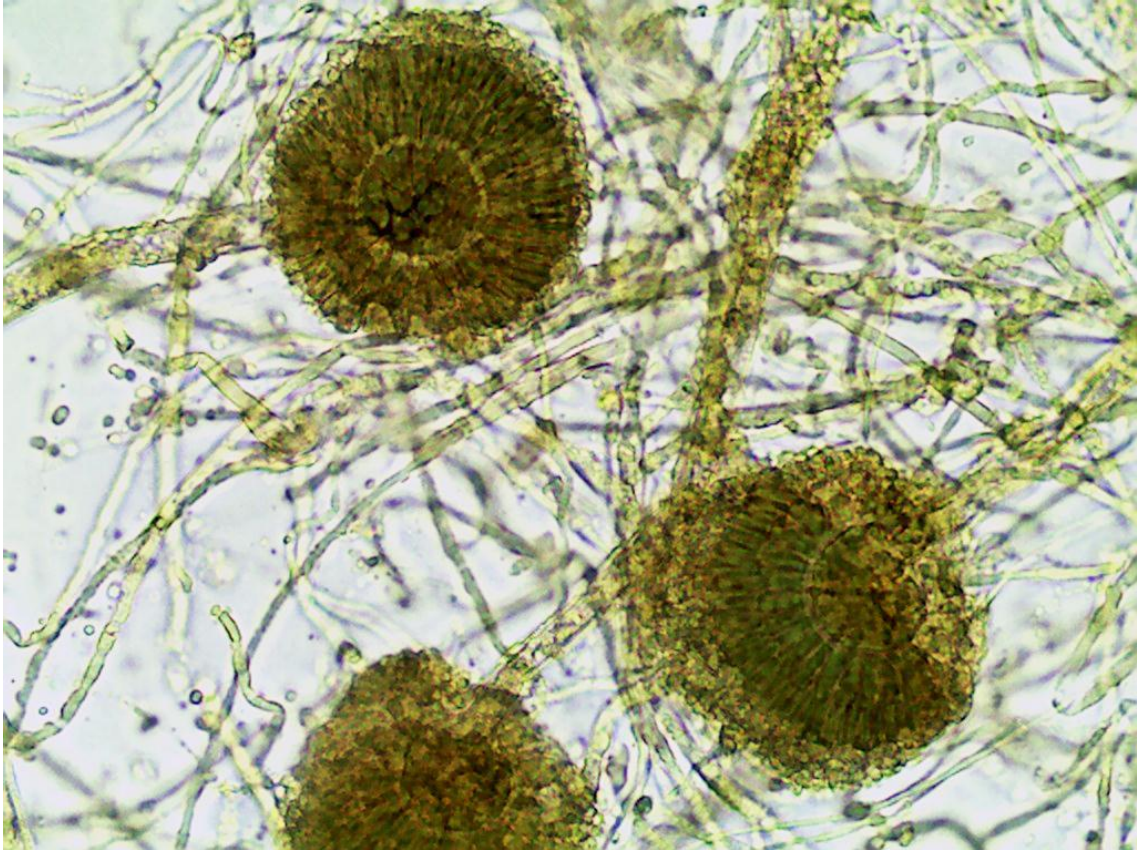
Lâmina 77: Exame direto de raspado couro cabeludo, 400x.



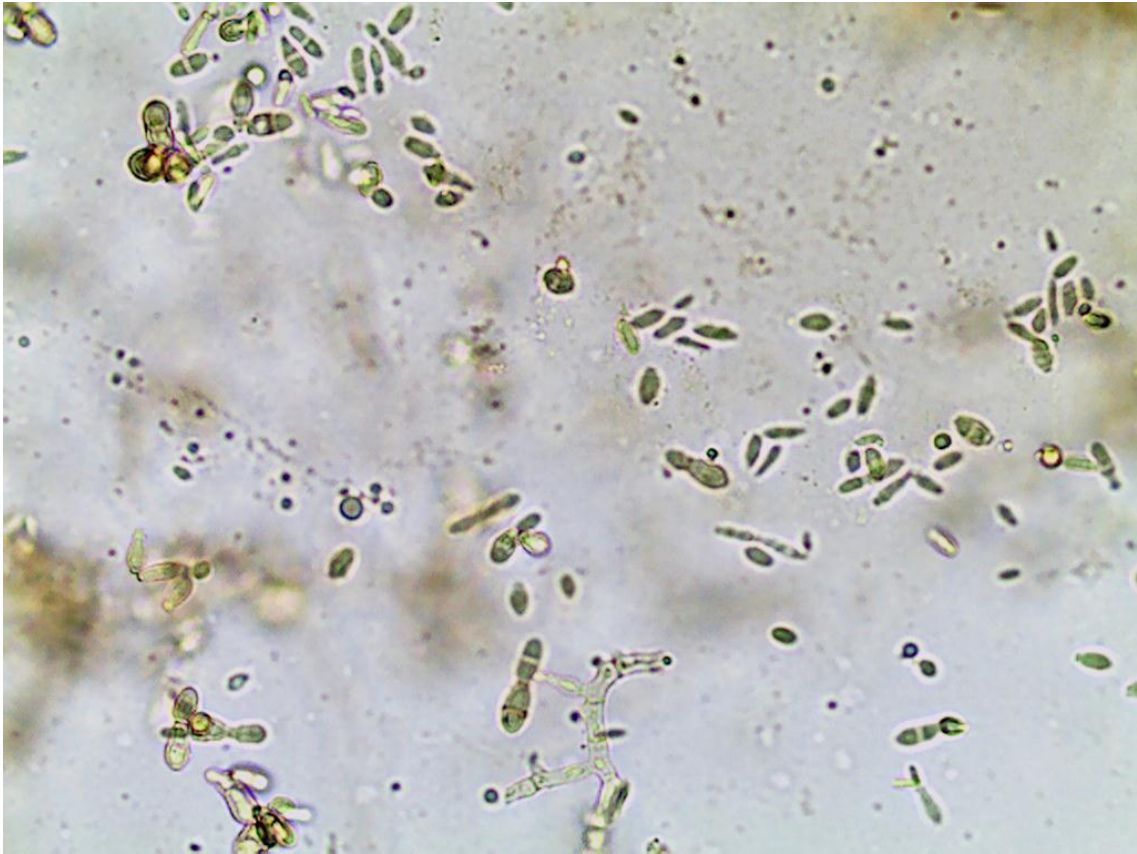
Lâmina 78: Micromorfologia de colônia, 400x.



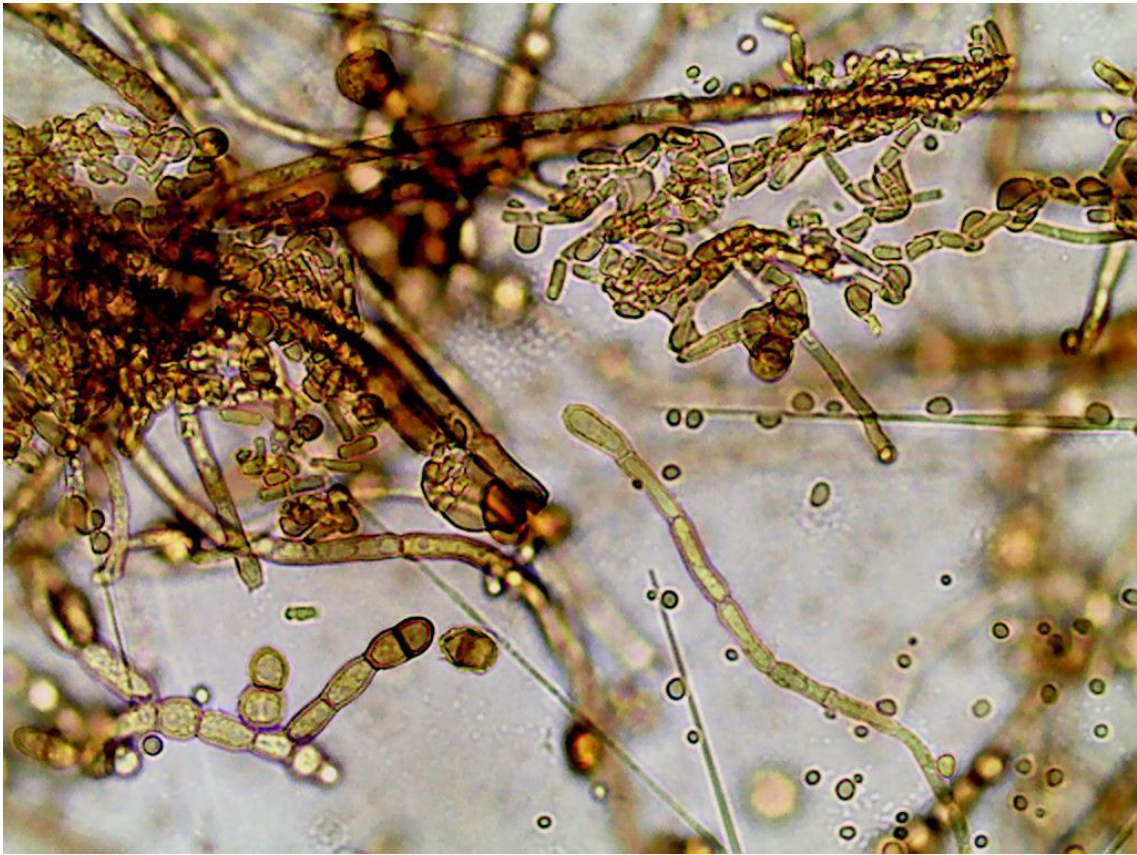Lâmina 79: Micromorfologia de colônia, 400x.



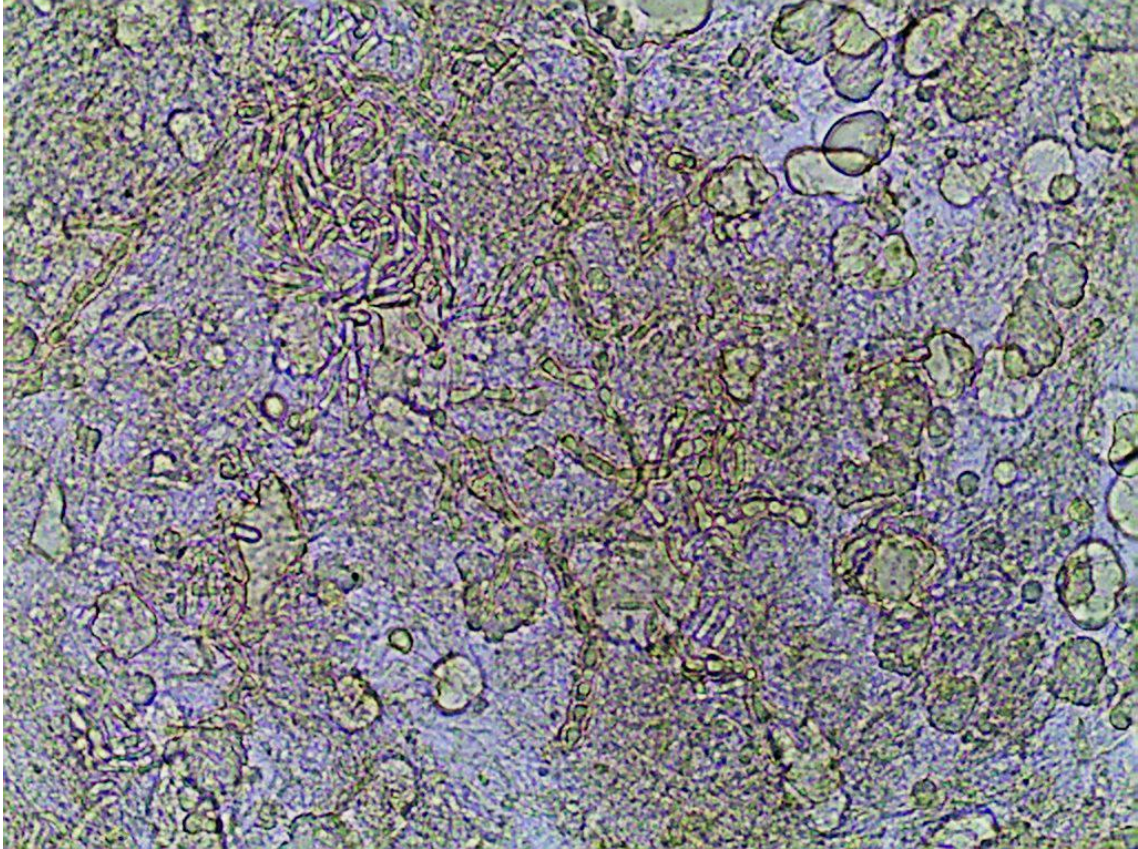
Lâmina 80: Micromorfologia de colônia de fungo demácio, 400x.



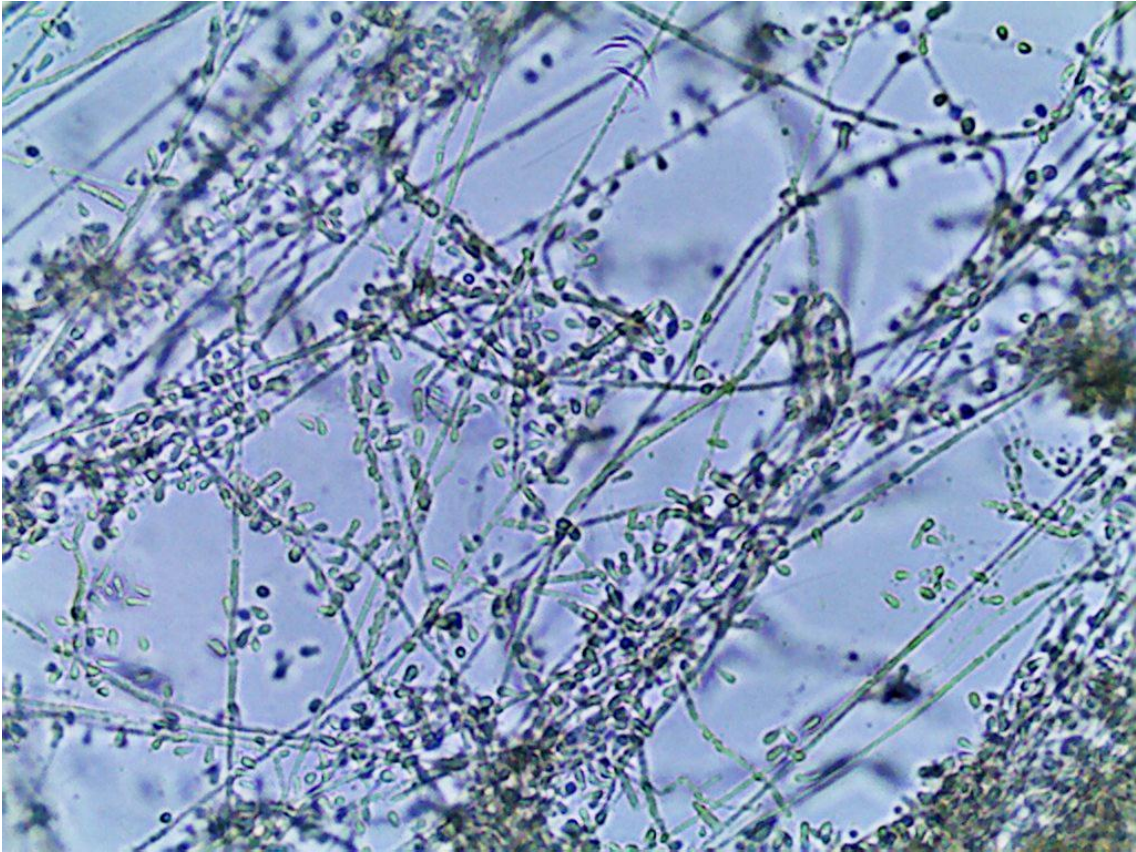
Lâmina 81: Micromorfologia de colônia, 400x.



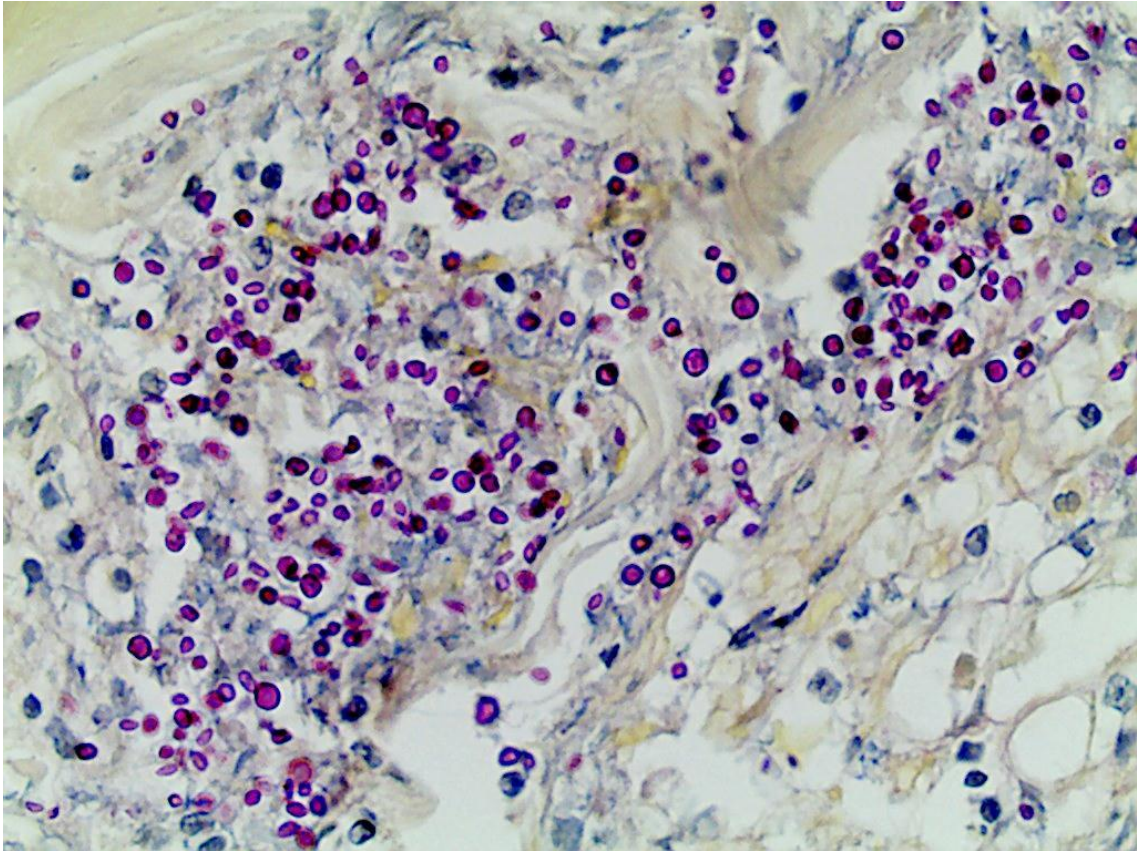
Lâmina 82: Exame direto de mancha castanha no pé, 400x.



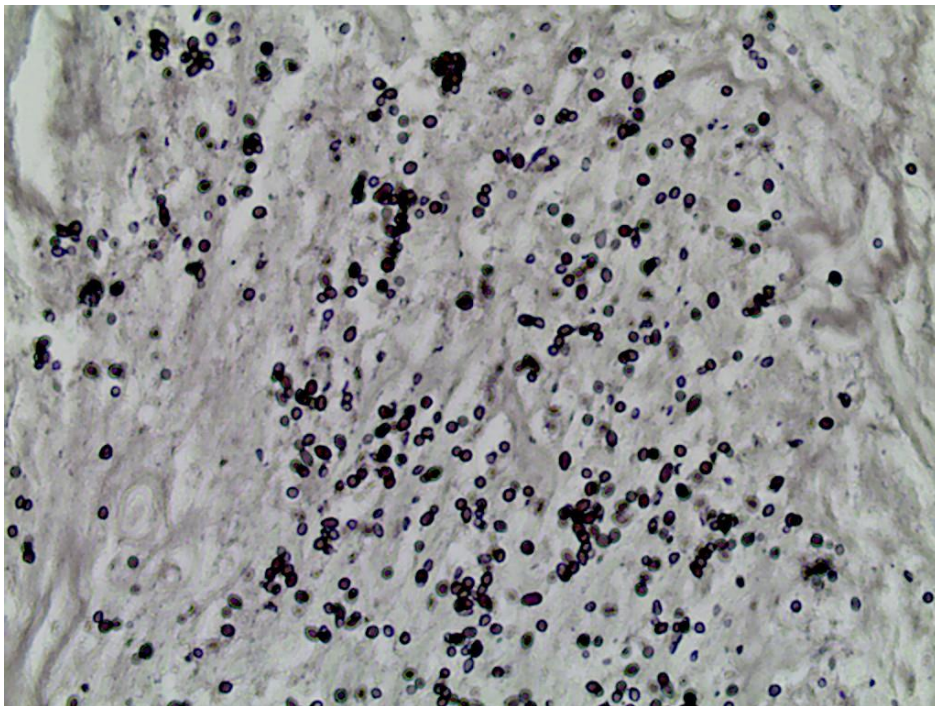
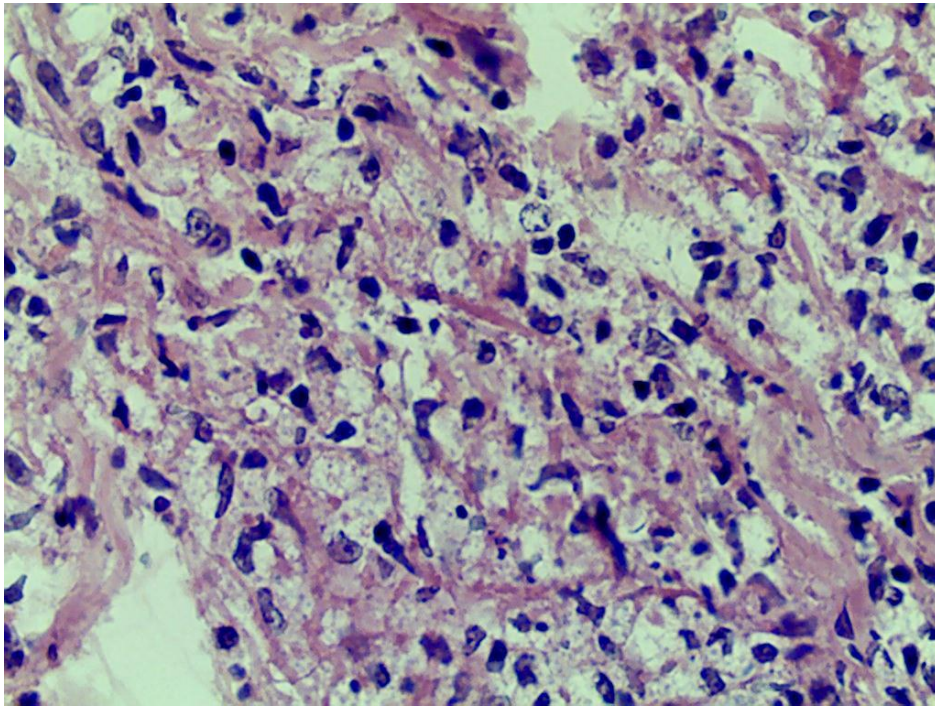
Lâmina 83: Micromorfologia de colônia, 400x.



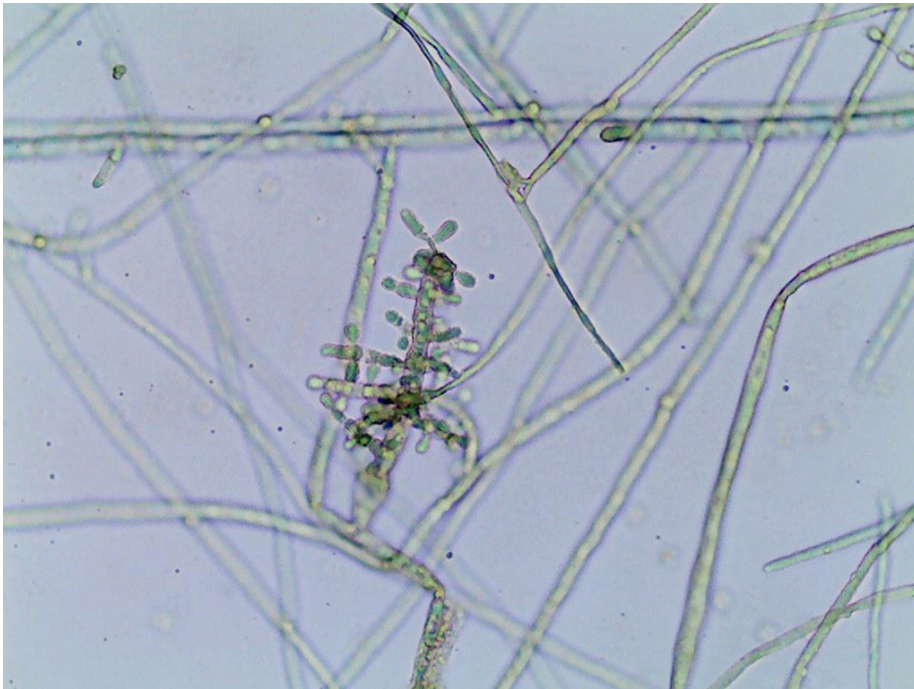

Lâmina 84: Exame histopatológico de lesão ulcerada na mão direita, que surgiu um mês após
bicada por psitacídeo da Amazônia (arara), PAS, 400x.



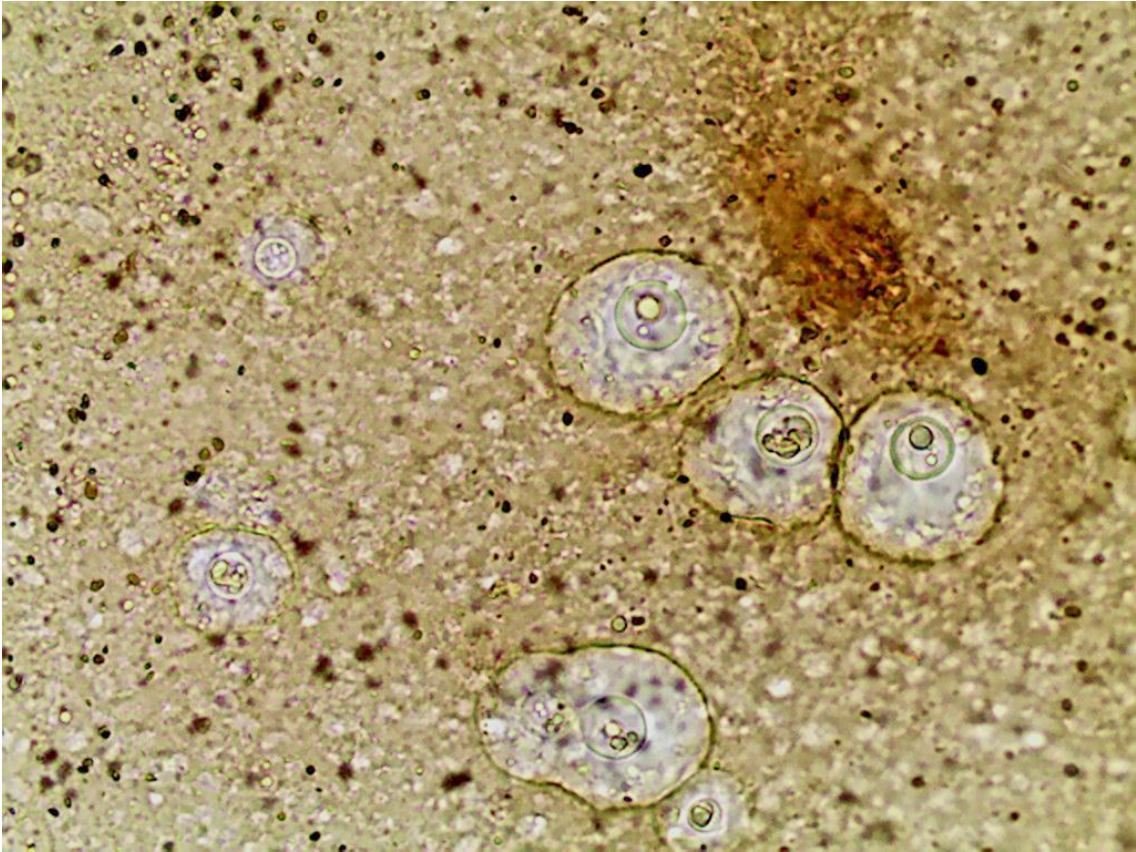
Lâmina 85: Exame histopatológico de lesão tipo molusco na face de paciente portador do vírus HIV, HE e Grocott respectivamente, 400x.



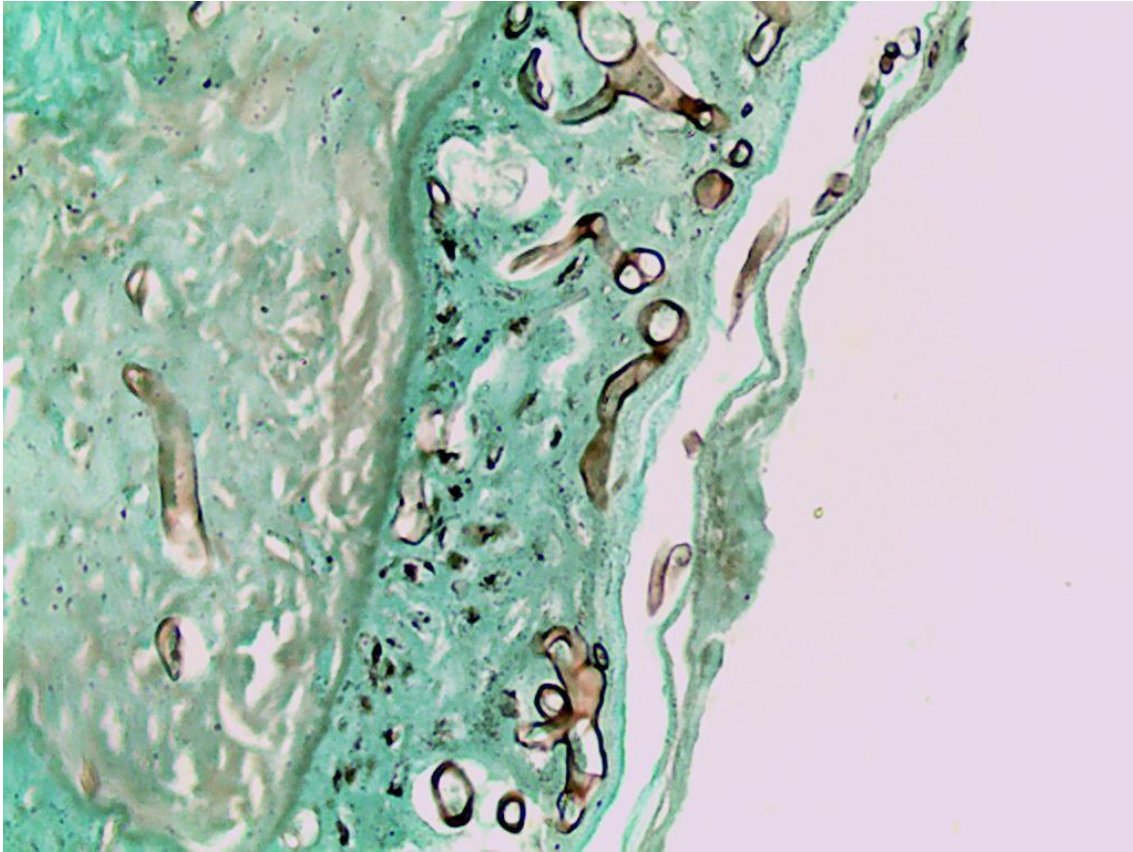
Lâmina 86: Micromorfologia de colônia, 400x.



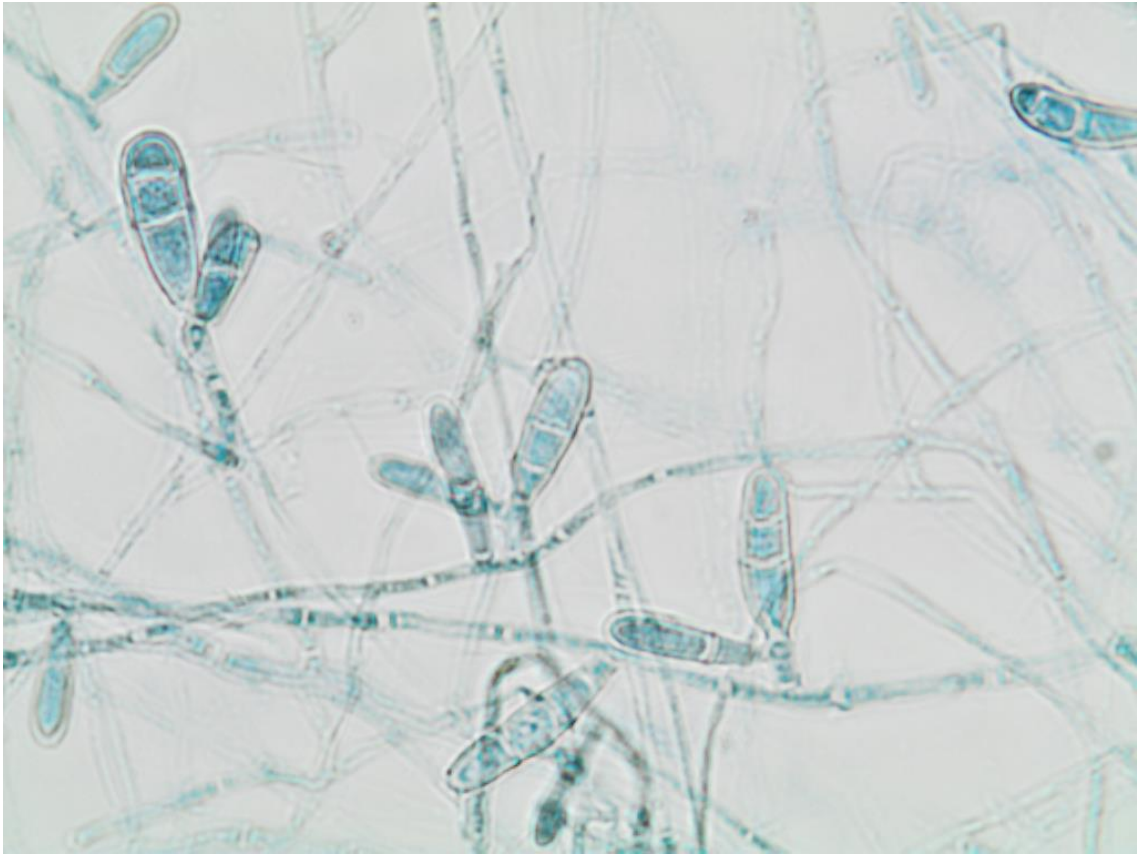
Lâmina 87: Exame direto de um abscesso, 400x.



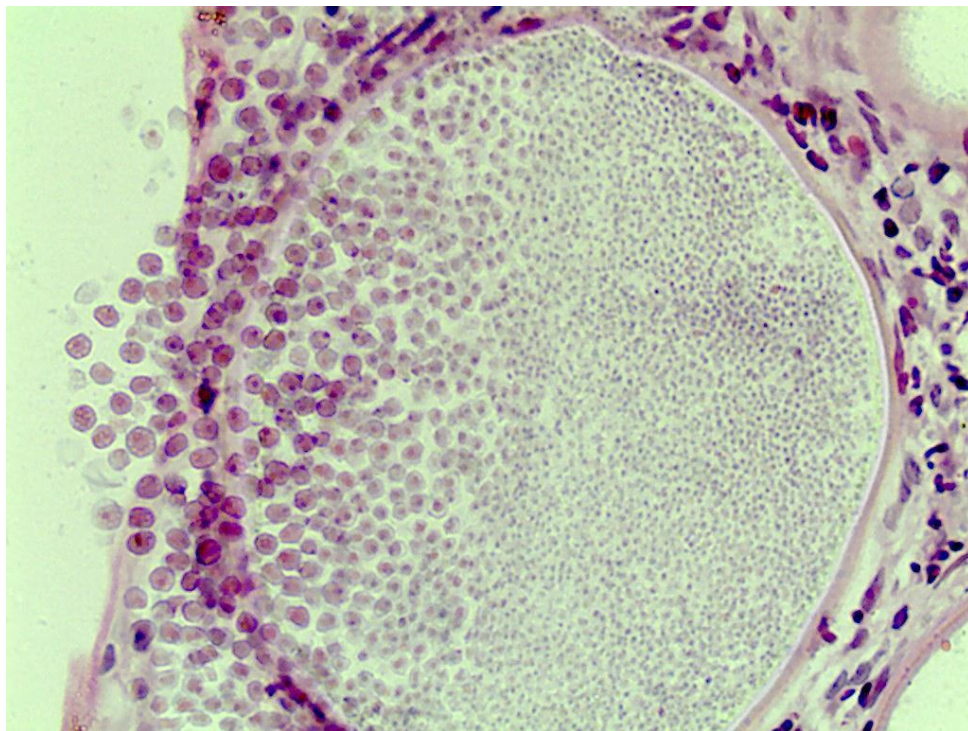
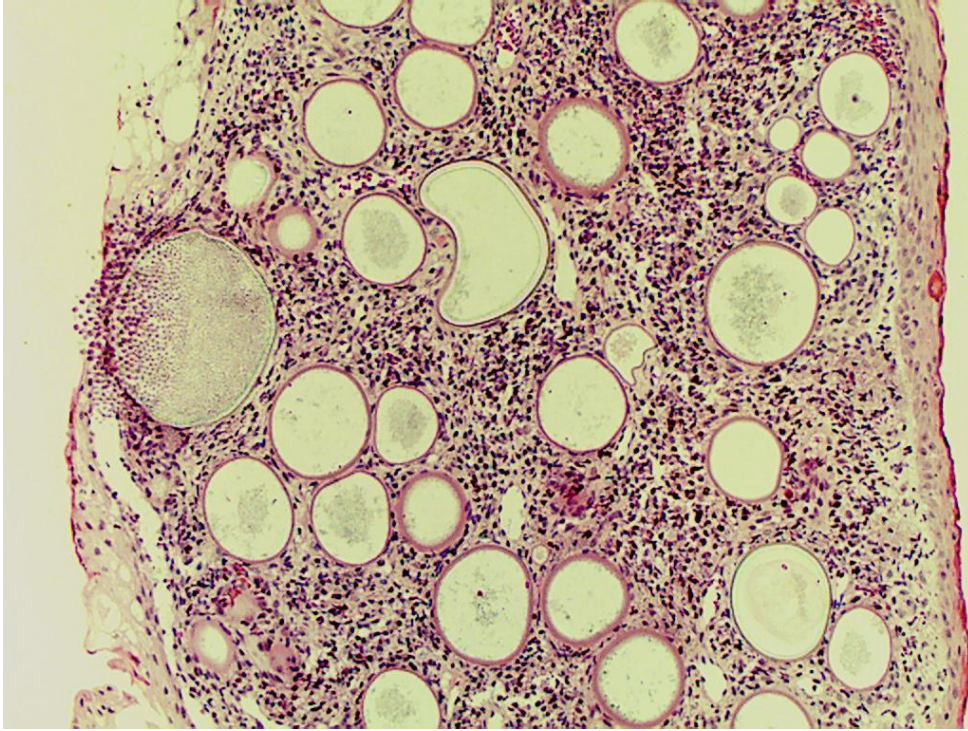
Lâmina 88: Exame histopatológico corado pelo Grocott, 400x.



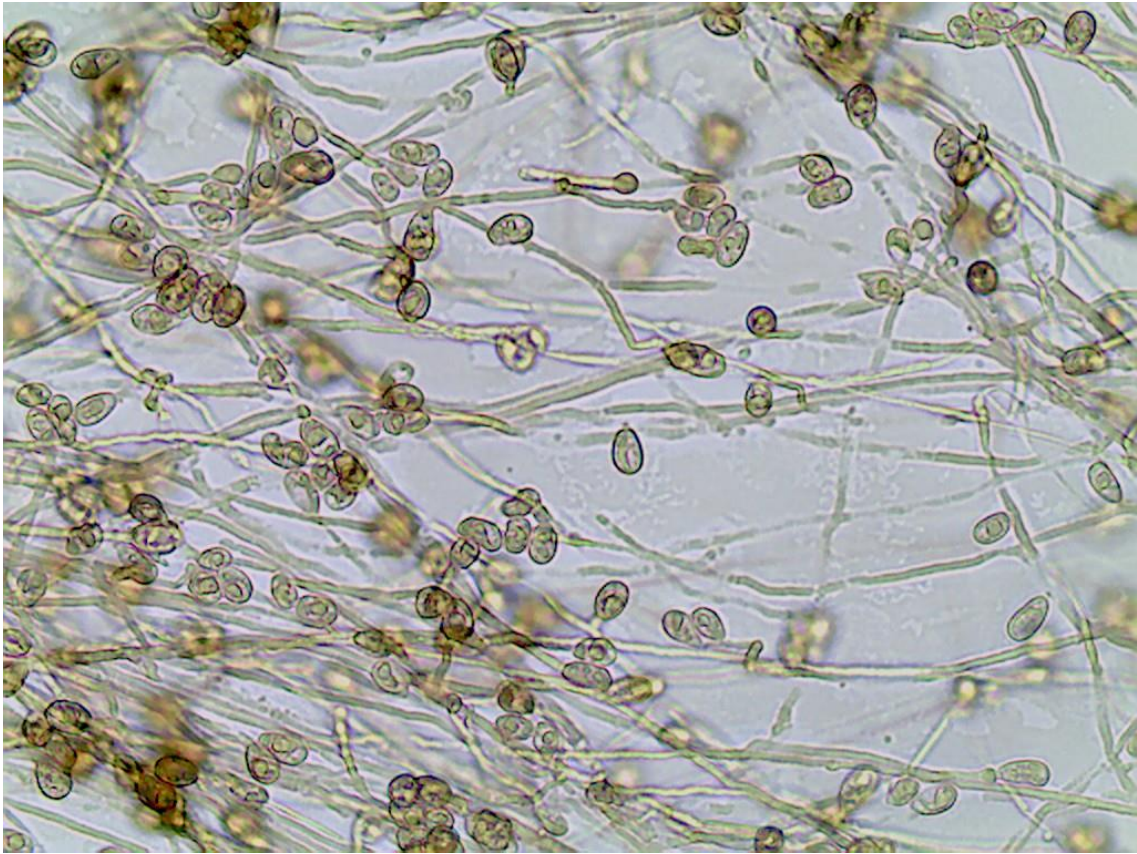
Lâmina 89: Micromorfologia de colônia, 400x.



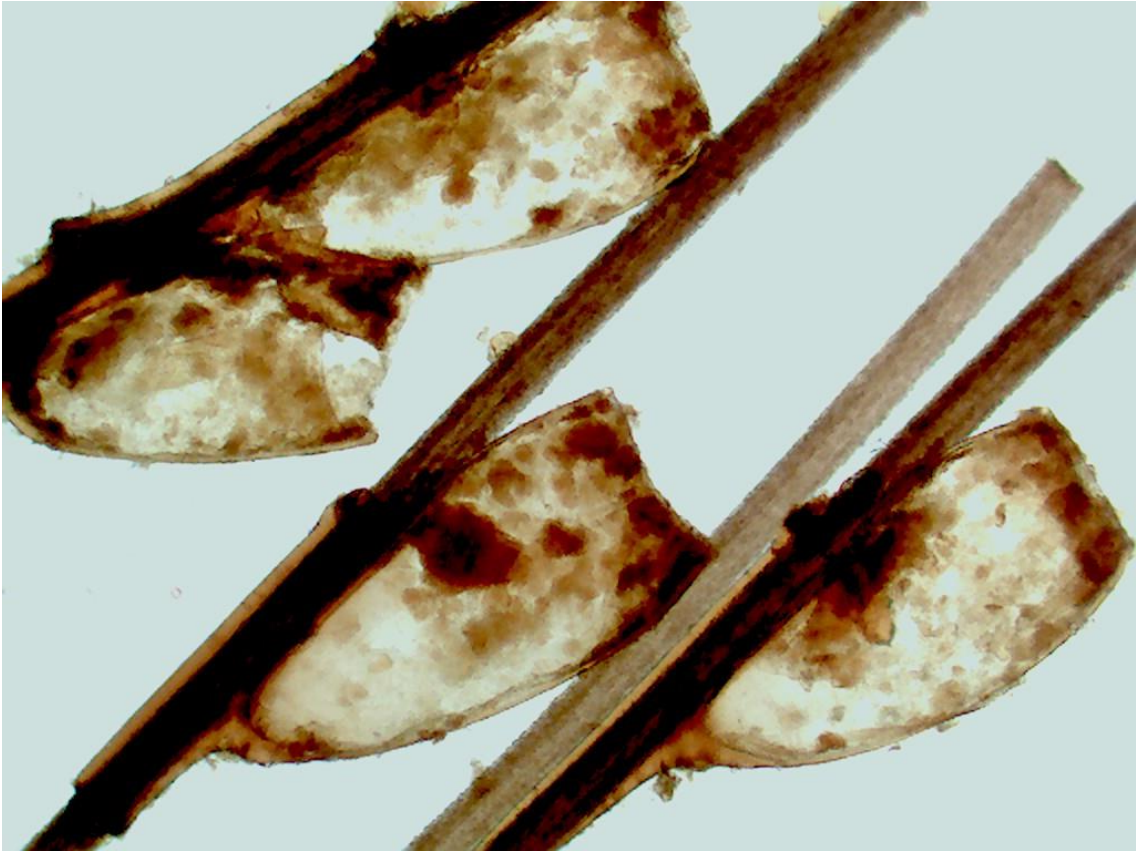Lâmina 90: Exame histopatológico de lesão da conjuntiva, HE, 100x e 400x.



Lâmina 91: Micromorfolgia de colônia, 400x.



Lâmina 92: Exame micológico direto de pelo, 4x.



Lâmina 93: Exame micológico direto de raspado de couro cabeludo.

